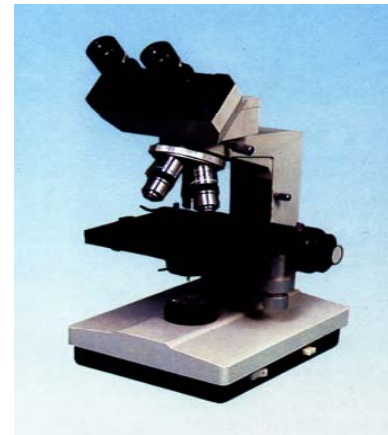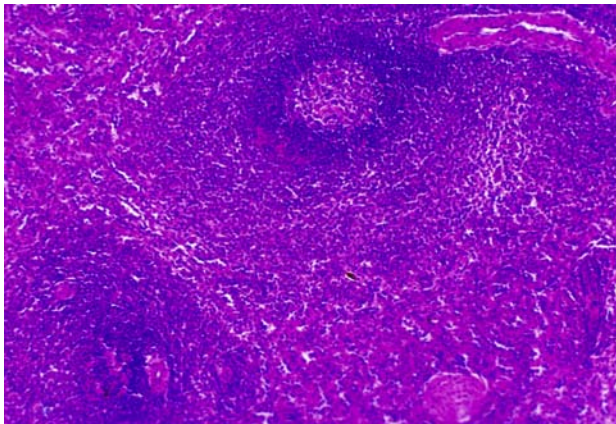



# Histology and Embryology



- Chapter 1 Introduction and Cell**
- Chapter 2 Epithelial tissue**
- Chapter 3 Connective Tissue**
- Chapter 4 Blood**
- Chapter 5 Cartilage and Bone**
- Chapter 6 Muscle Tissue**
- Chapter 7 Nerve Tissue**
- Chapter 8 Circulatory System**
- Chapter 9 Immune System**
- Chapter 10 Skin**
- Chapter 11 Digestive Tract**
- Chapter 12 Digestive Gland**
- Chapter 13 Respiratory System**
- Chapter 14 Urinary System**
- Chapter 15 Endocrine System**
- Chapter 16 Sense Organ**
- Chapter 17 Male Reproduction**
- Chapter 18 Female Reproduction**
- Chapter 19 Embryology 1**
- Chapter 20 Embryology 2**

# Chapter 9 Immune System

## I Slides

## **II Sections**

NO.34 thymus

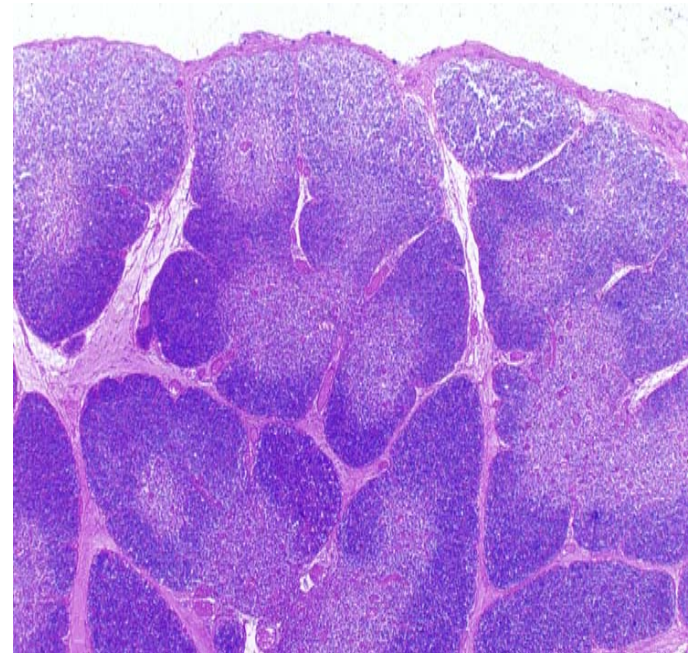
NO.36 lymph node

NO.37 spleen

NO.38 tonsil

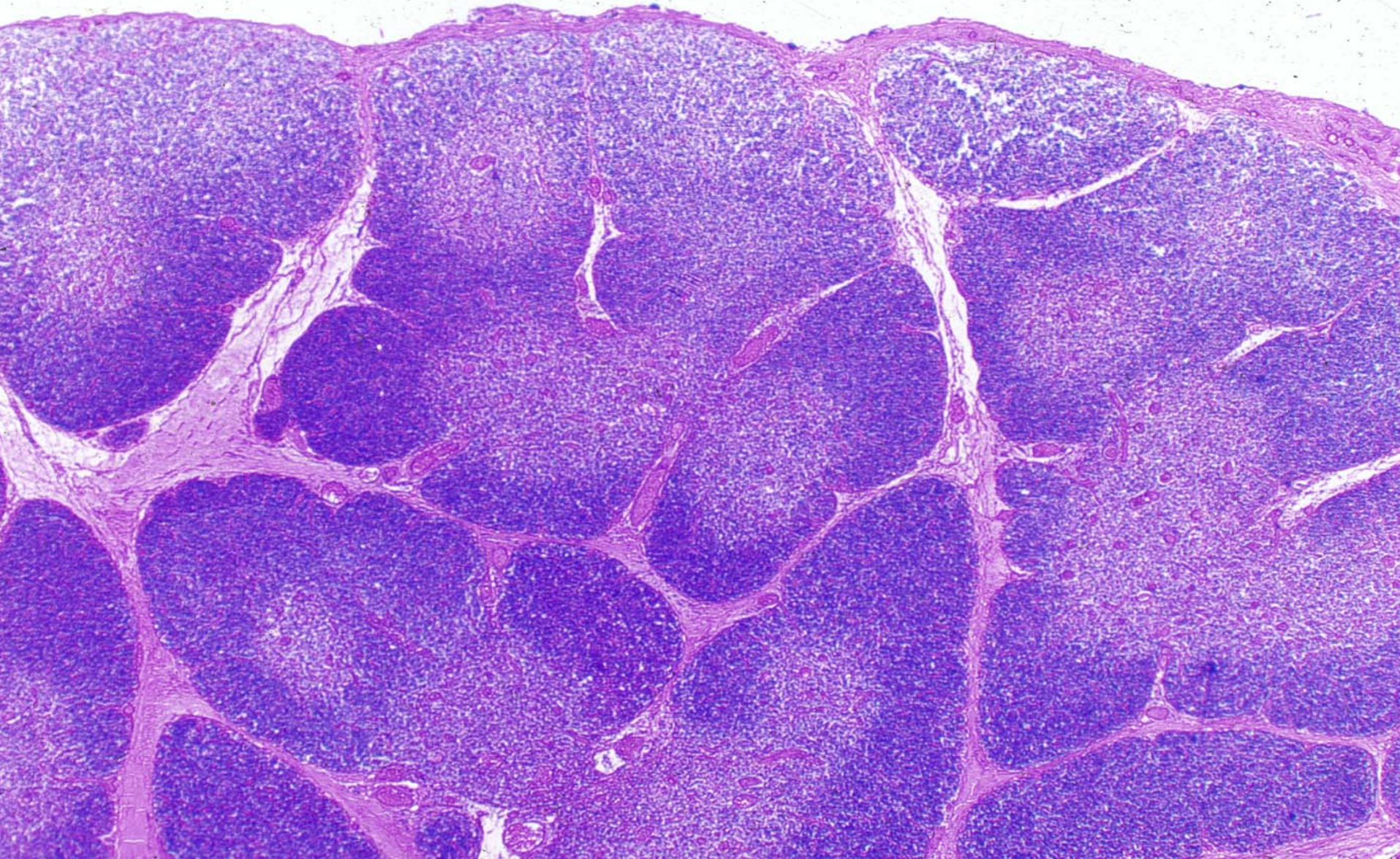
## **III EM photos: 35~39**

## IV Summary

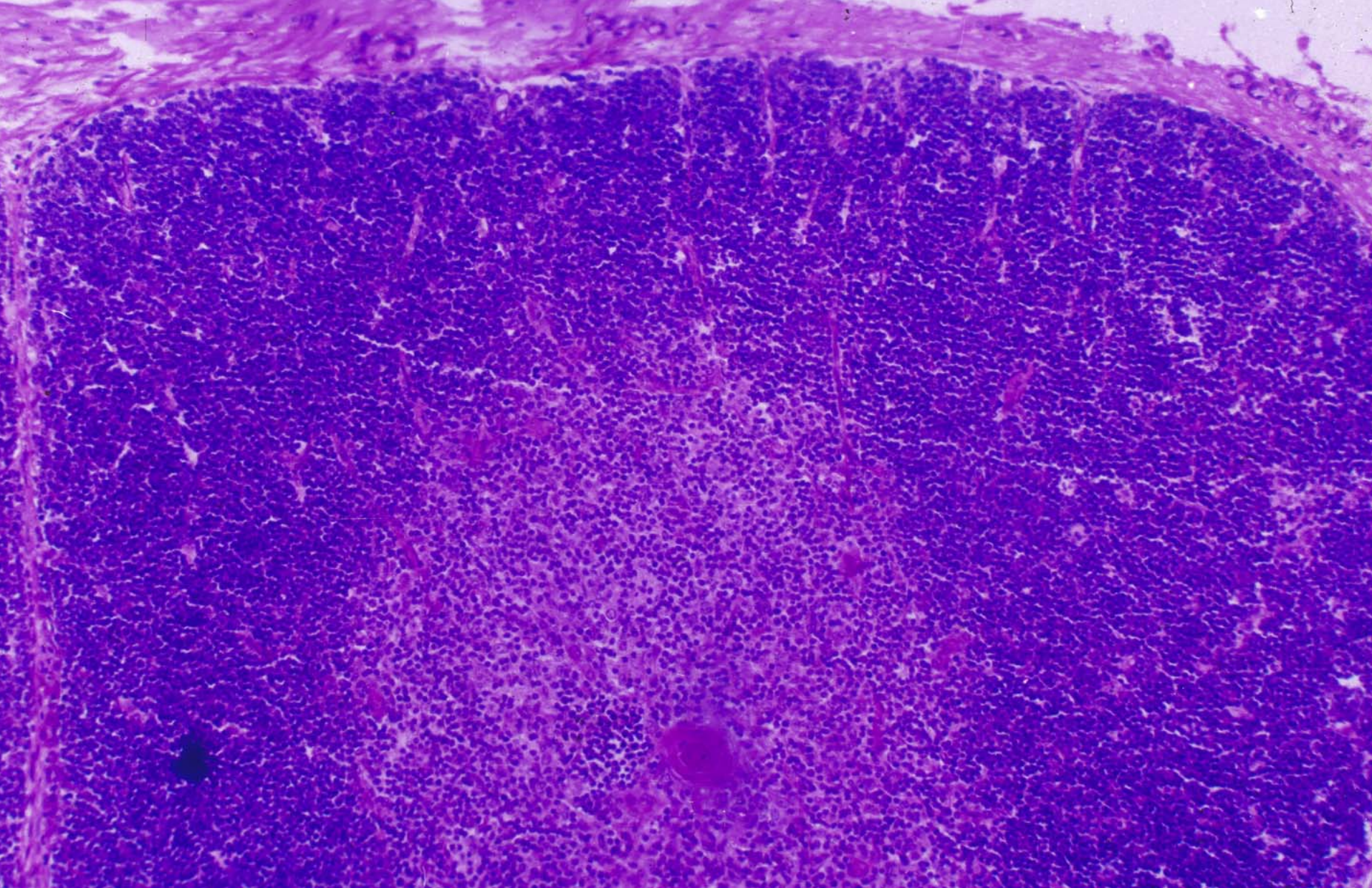


## 四、小结：

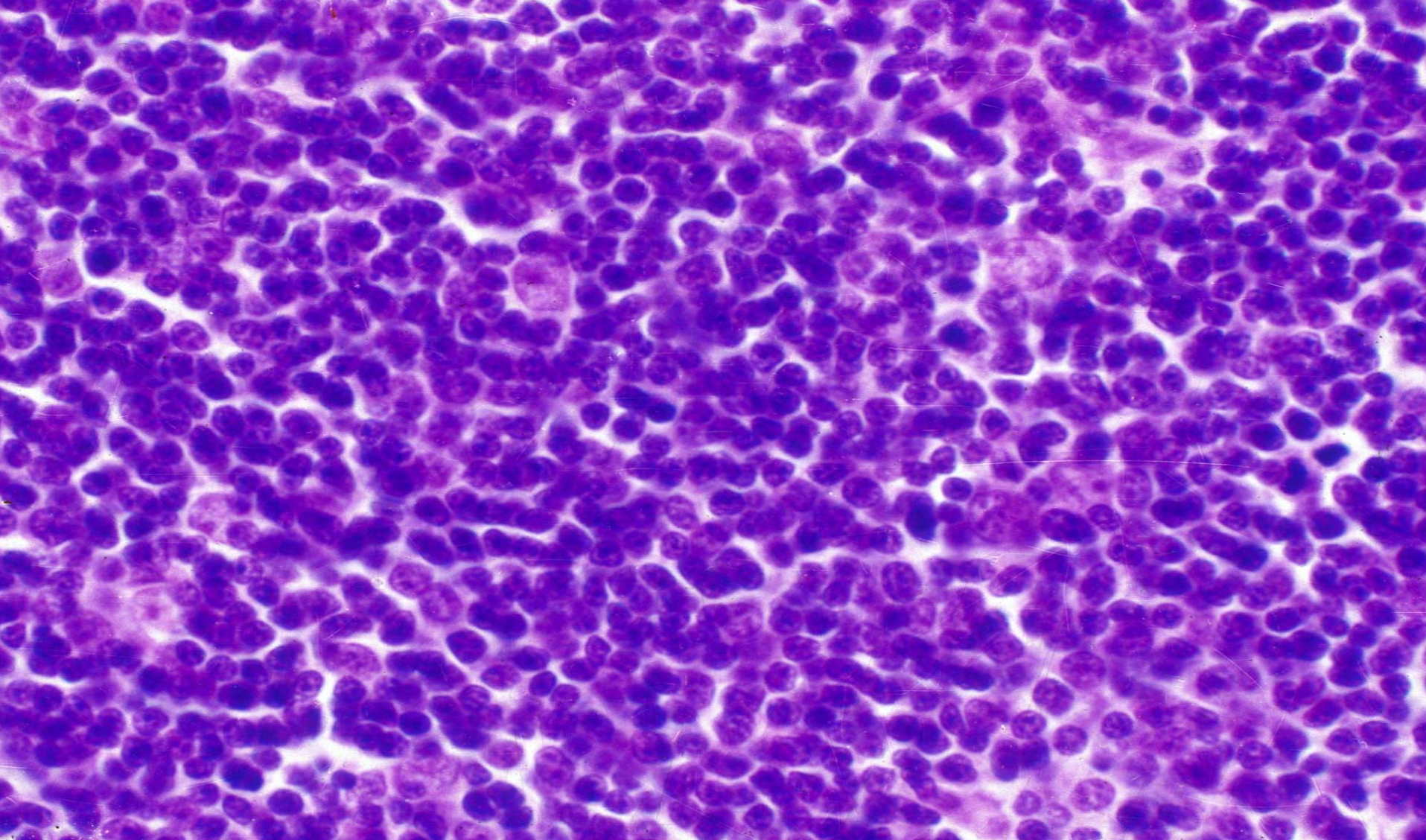
- 淋巴小结与弥散淋巴组织的结构与功能
- 淋巴结与脾的一般结构与功能



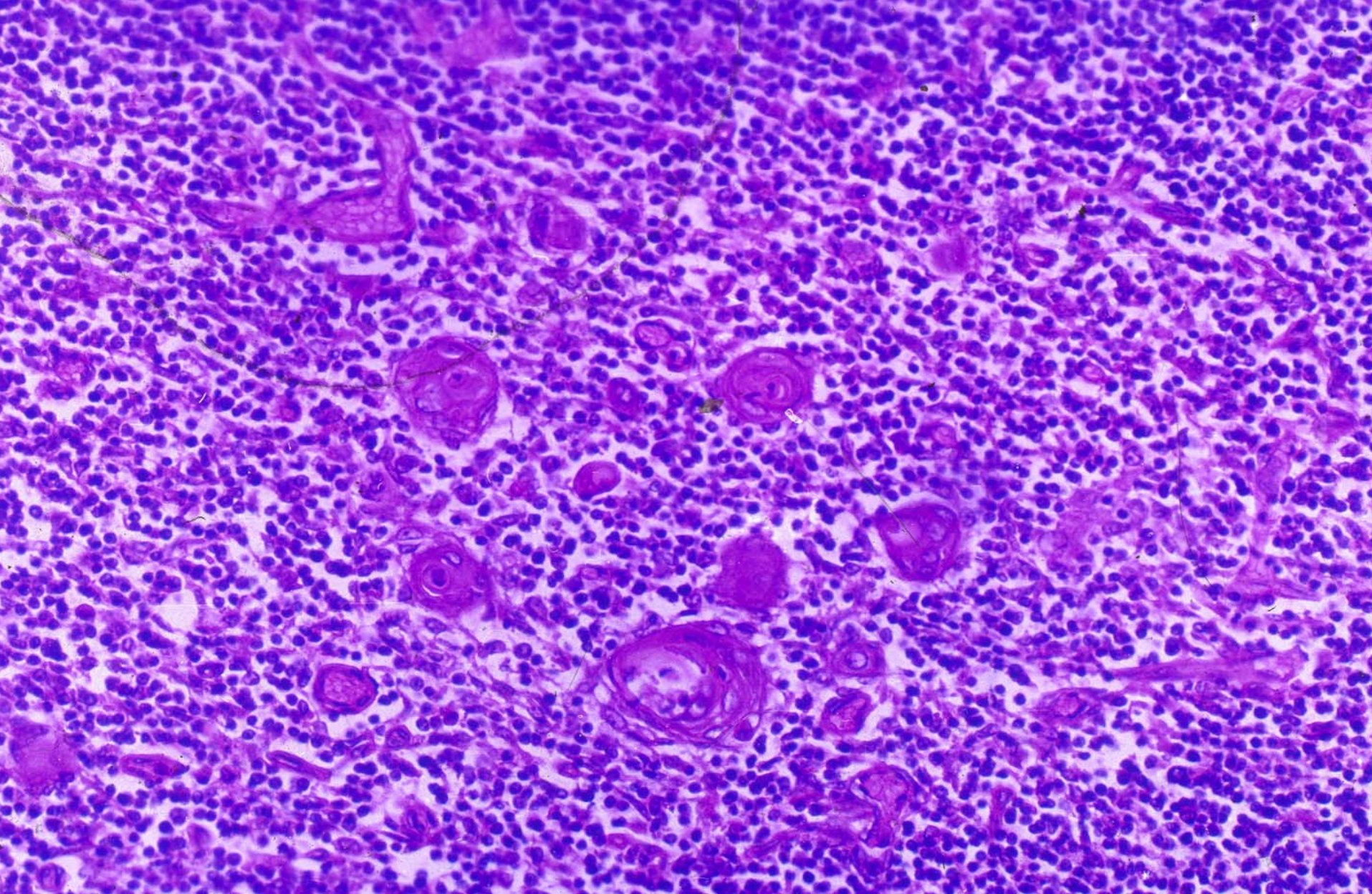
thymus



cortex of thymus

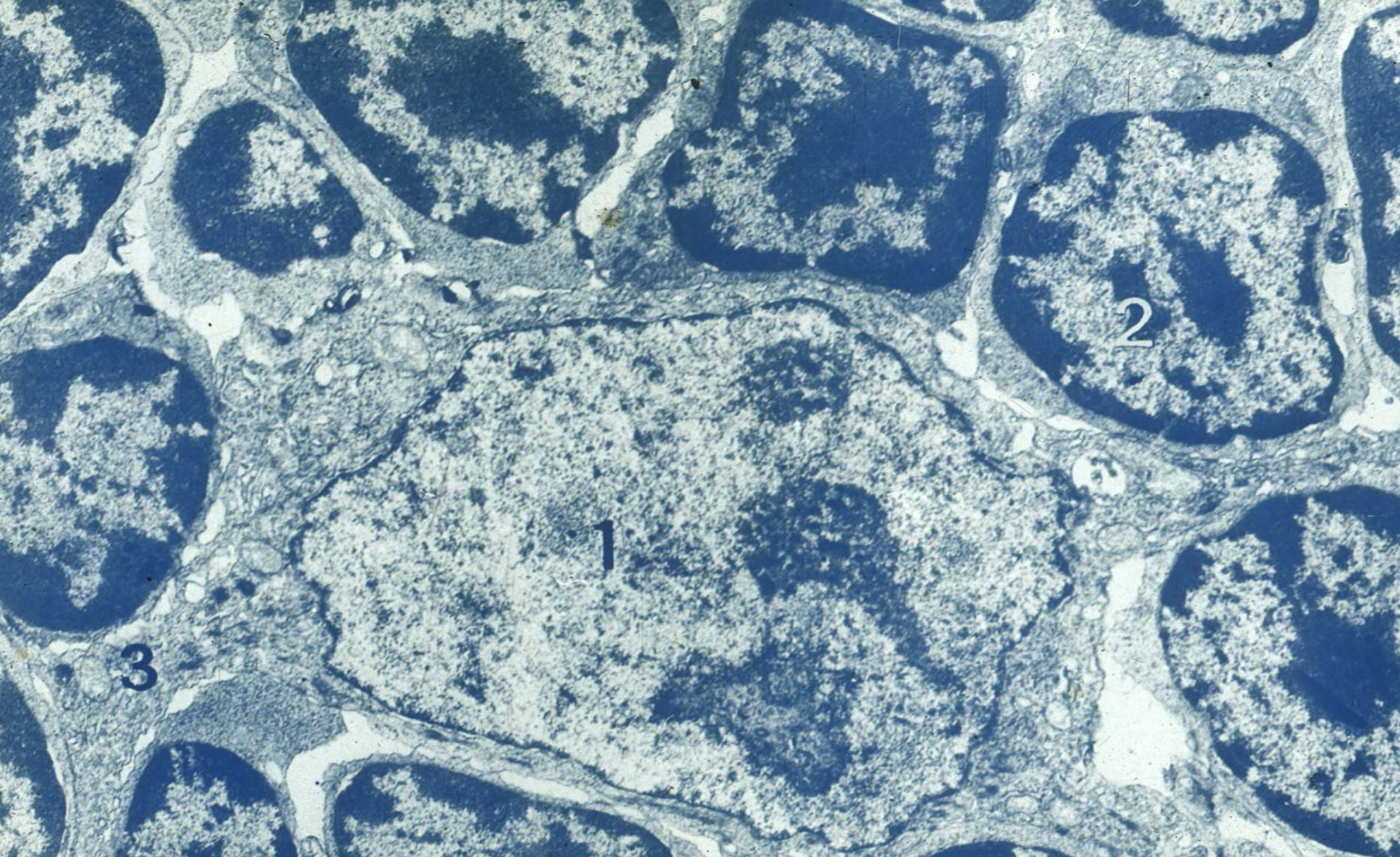


cortex of thymus

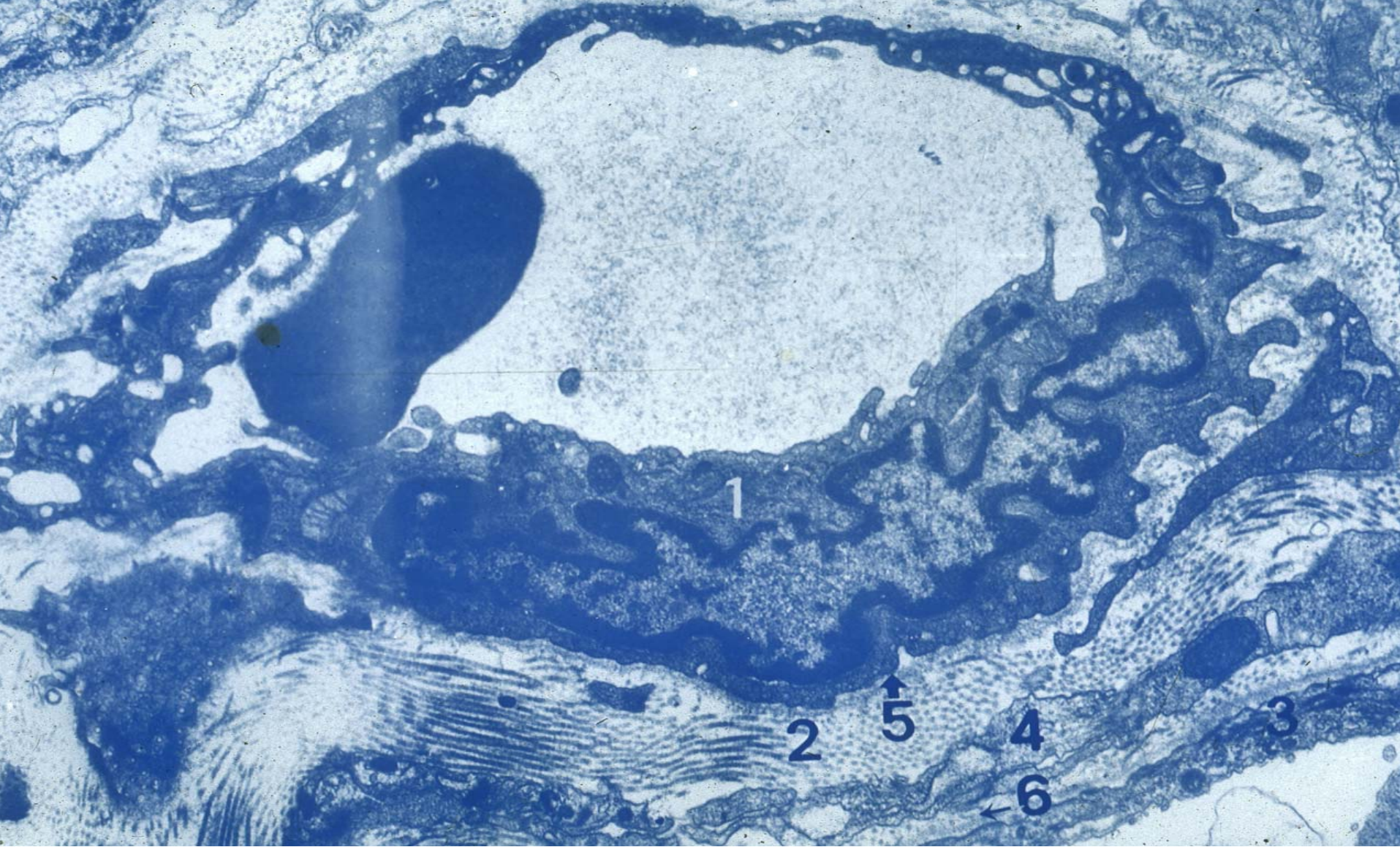


**medulla**

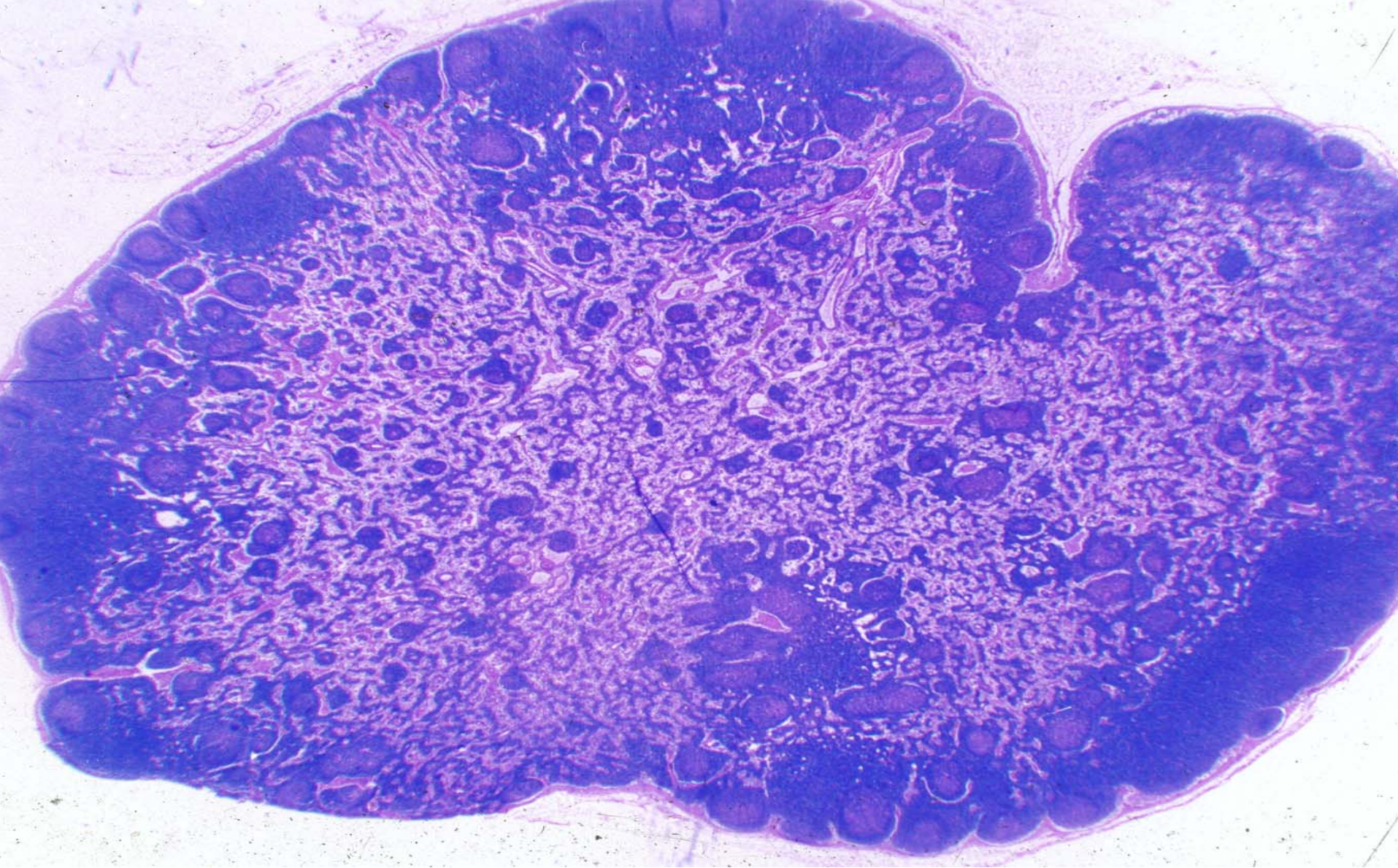




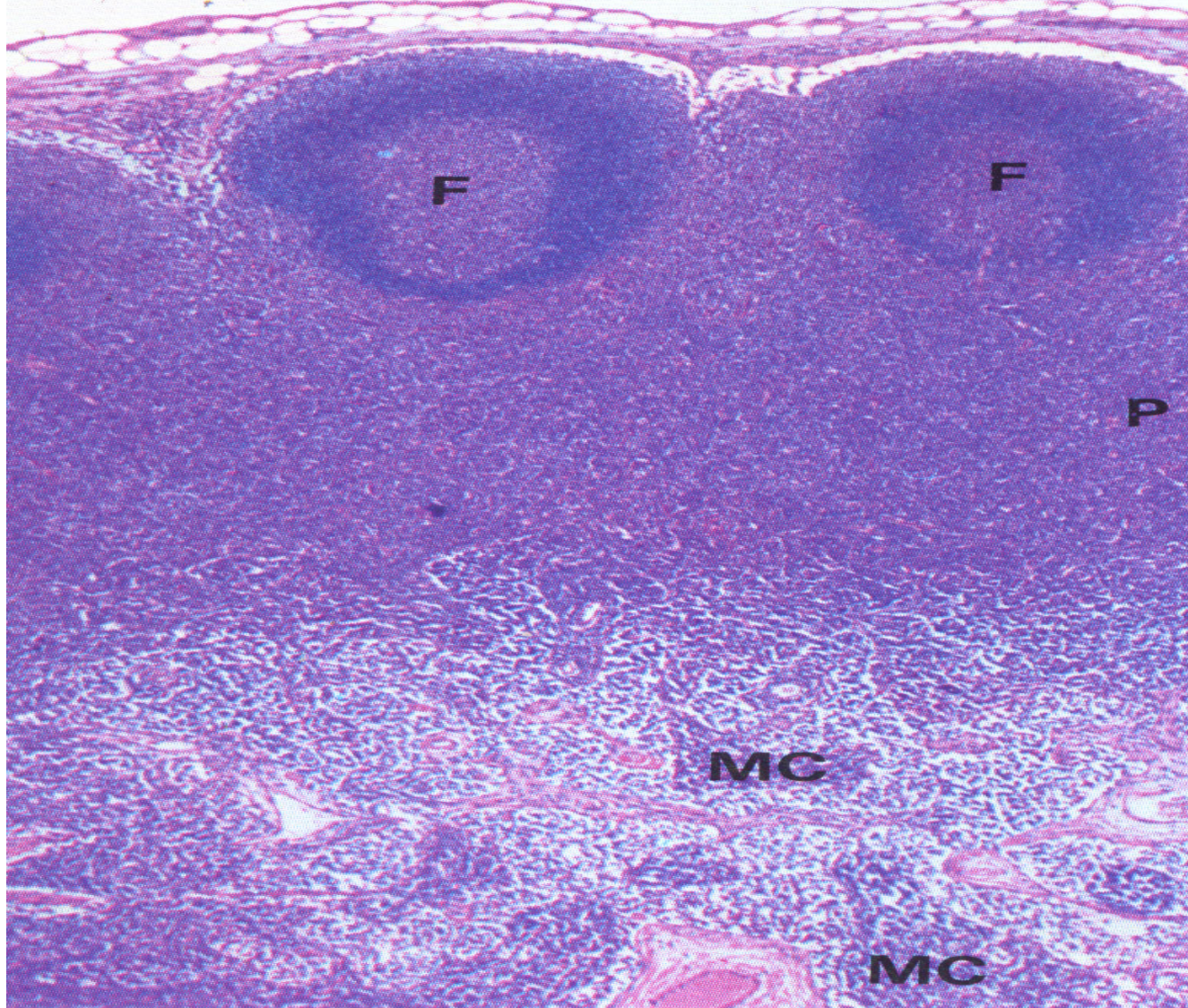
**satellite epithelial cell**



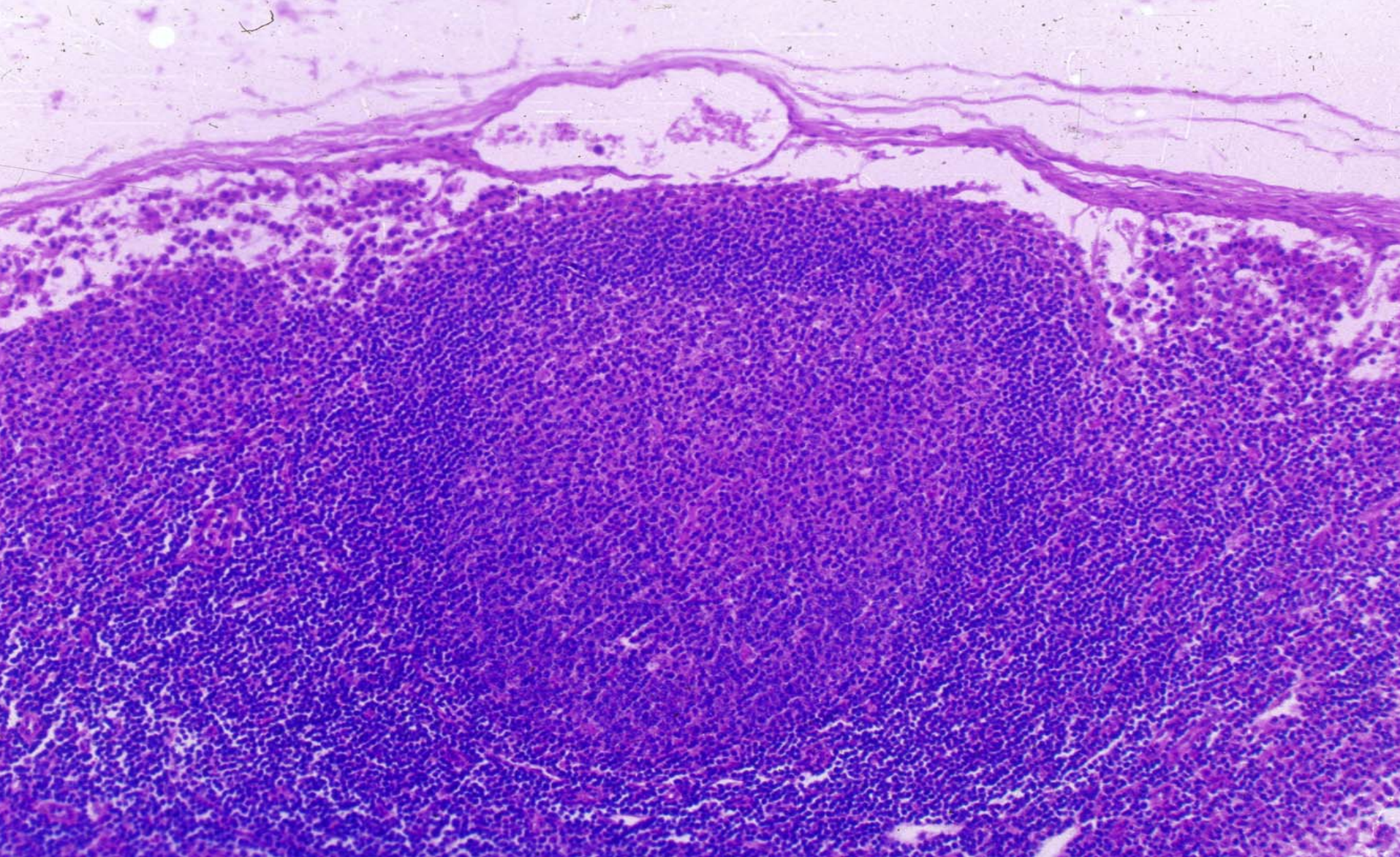
**Blood thymus barrier**



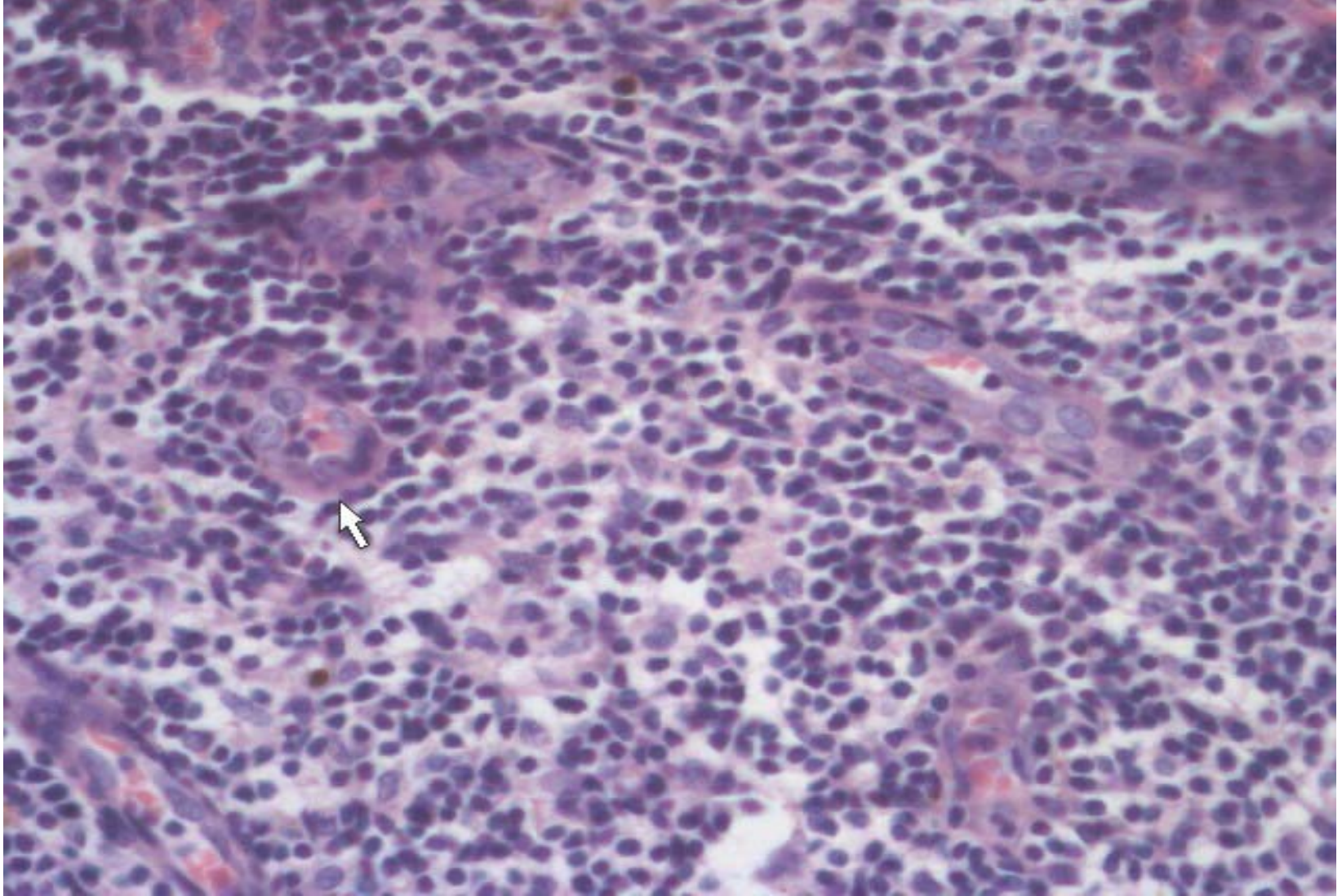
**Lymph node**



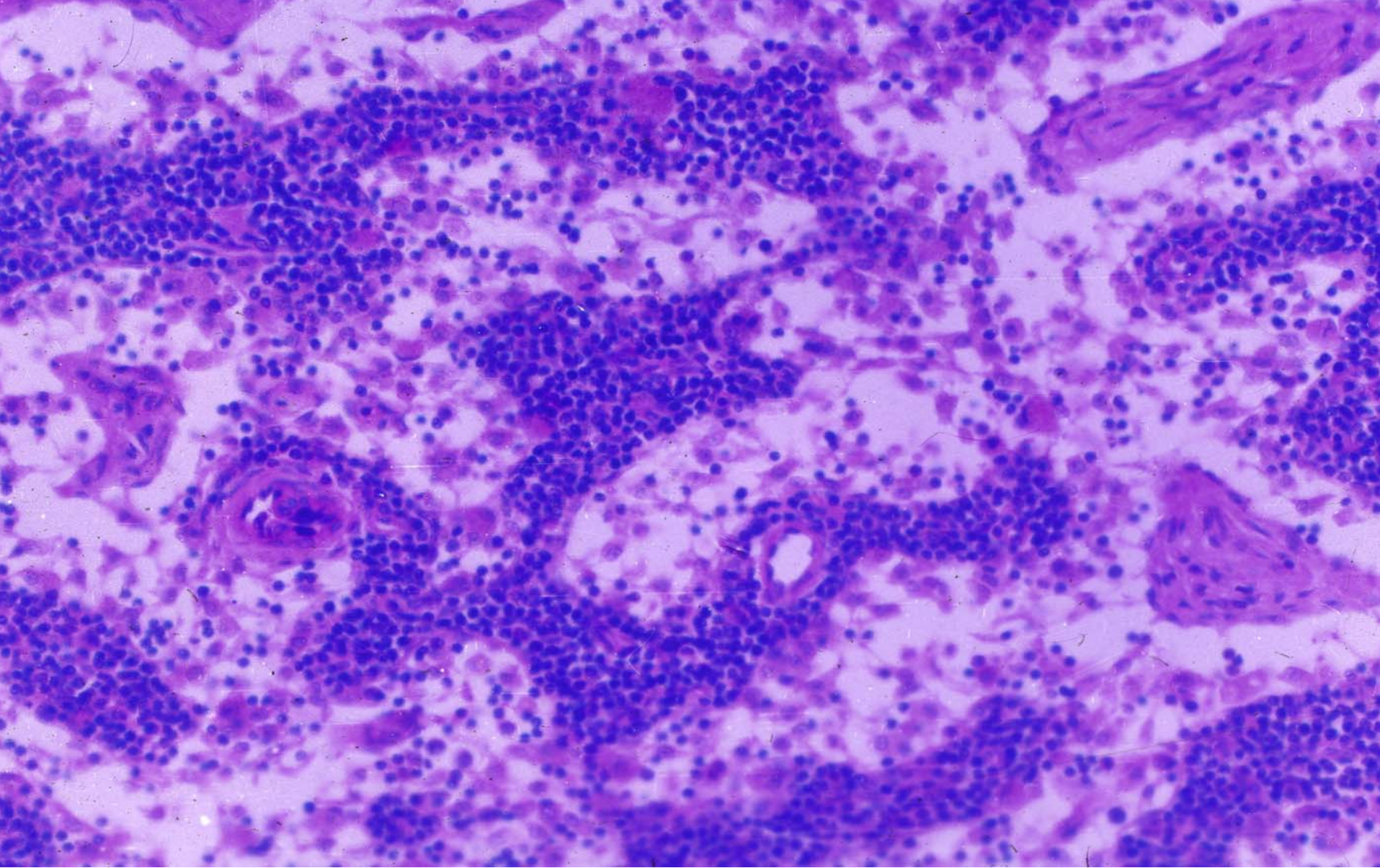
**Lymph node**



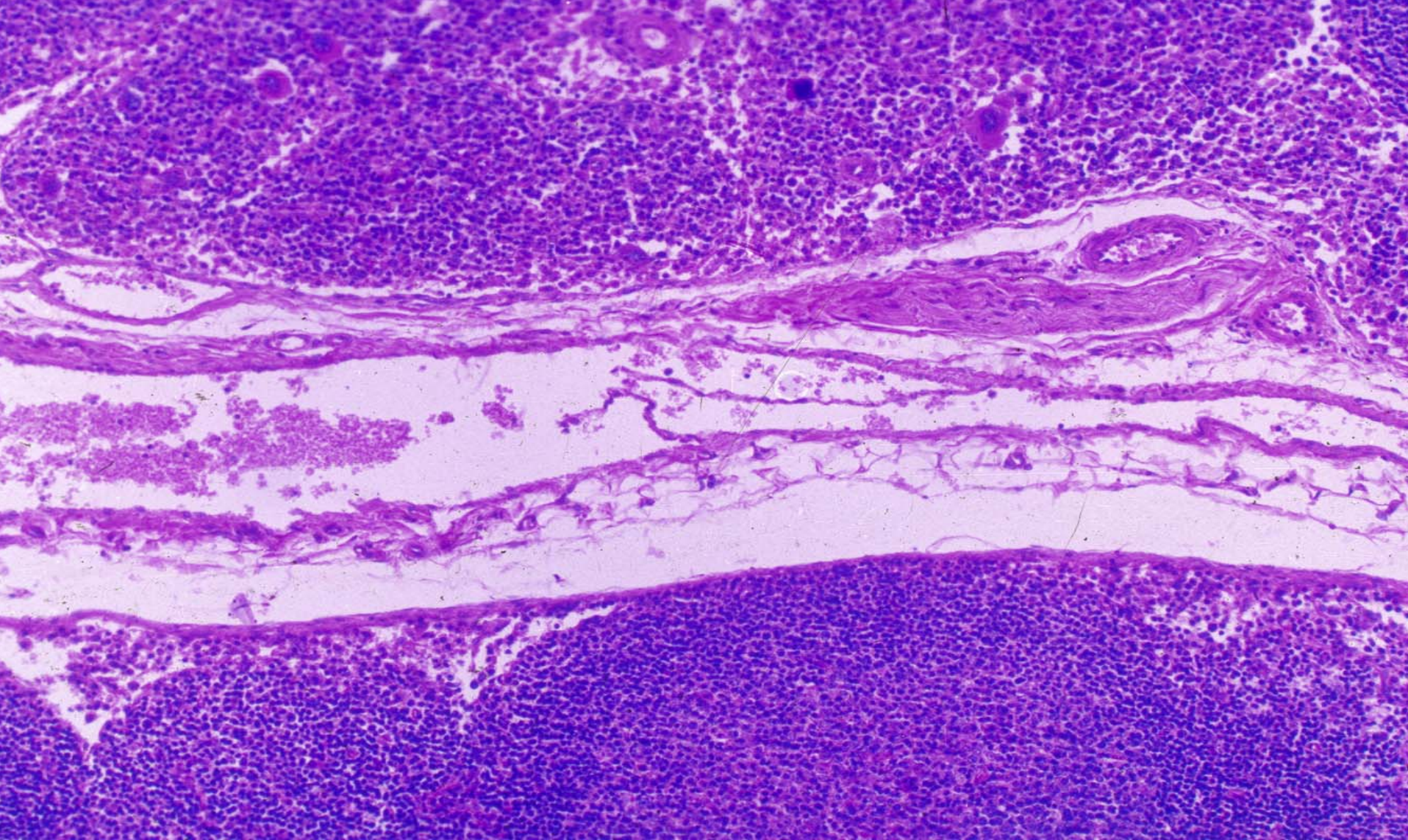
**cortex**



**Postcapillary venules**

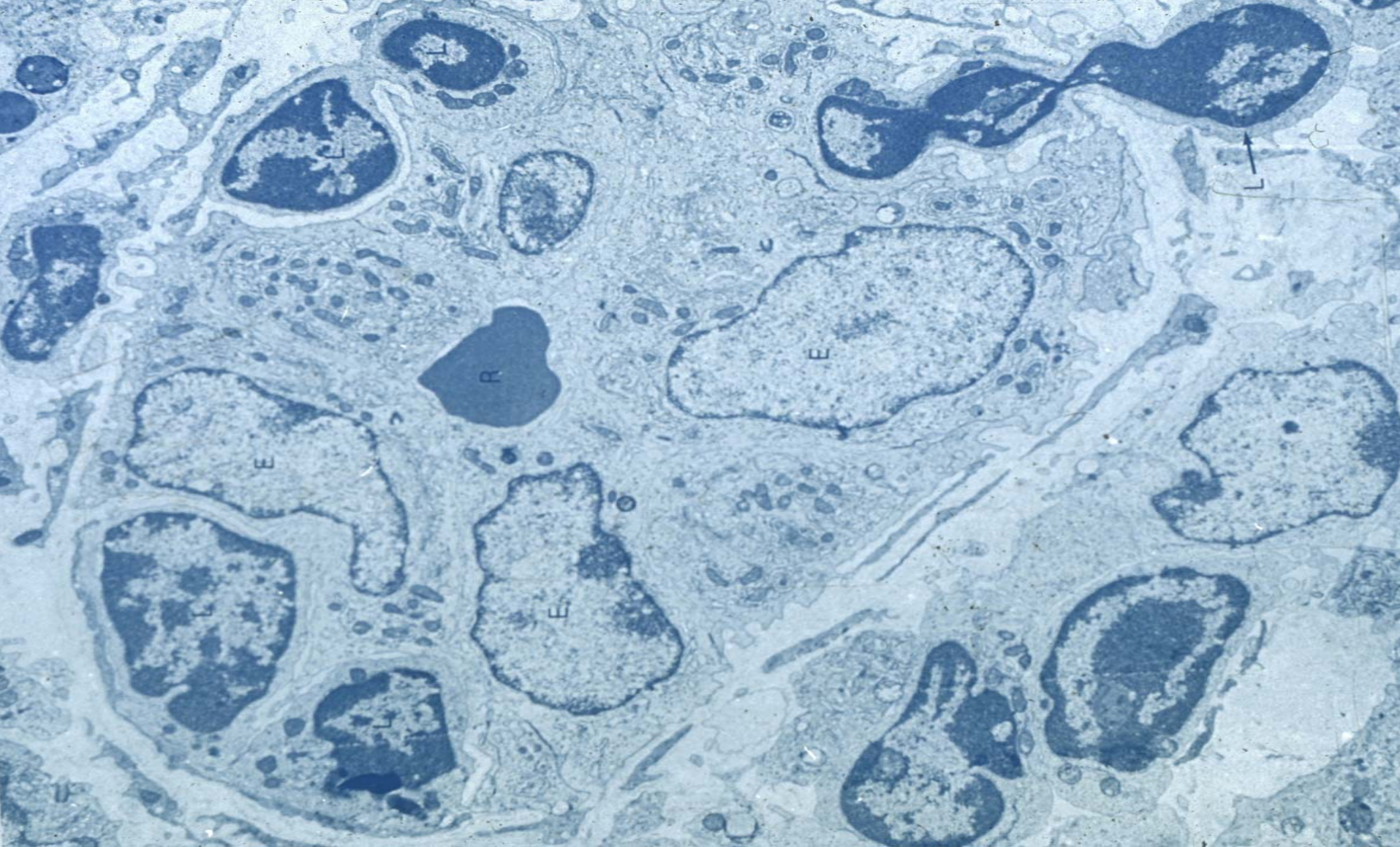


**medulla**

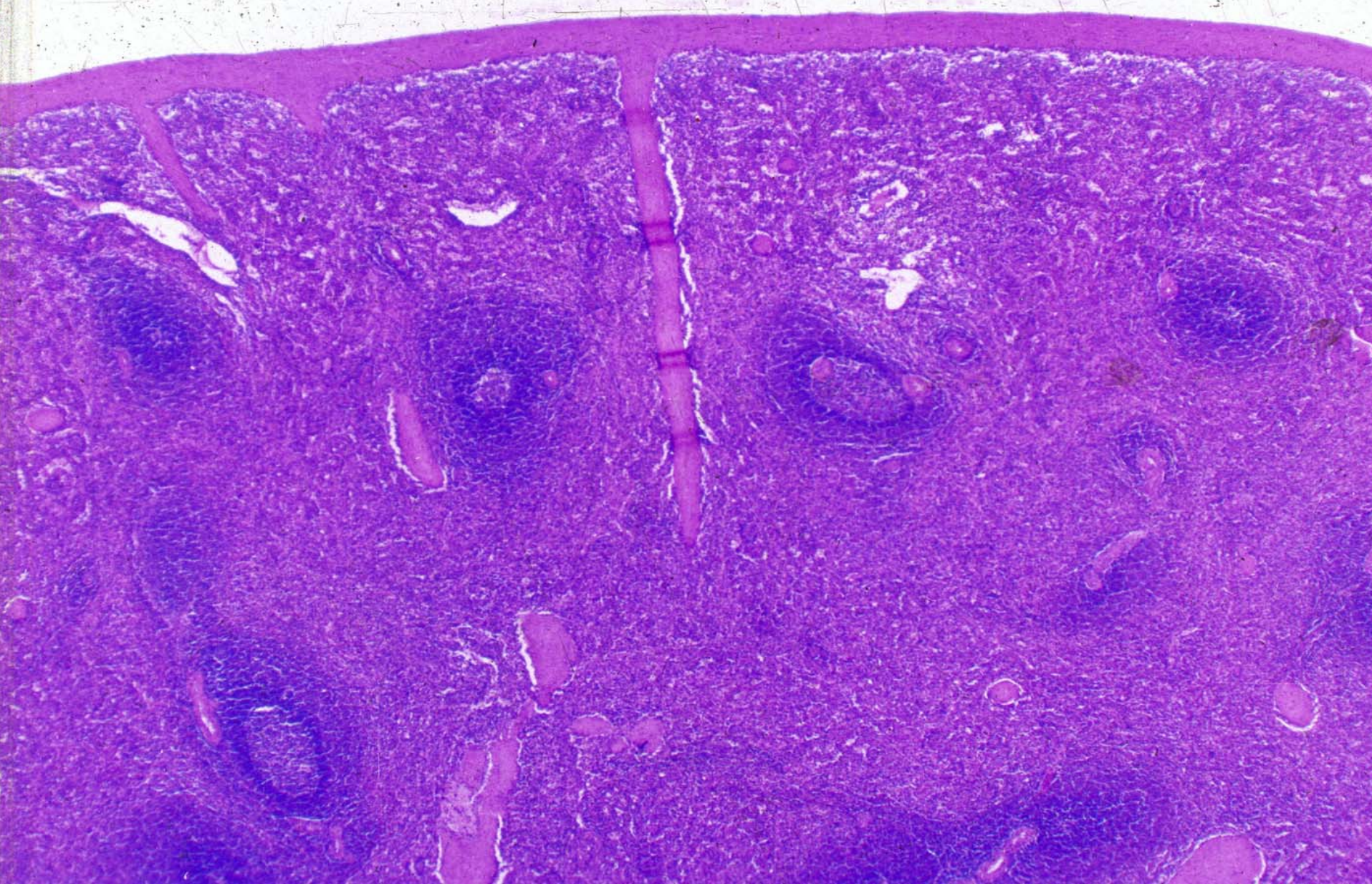


**Efferent lymphatic vessel**

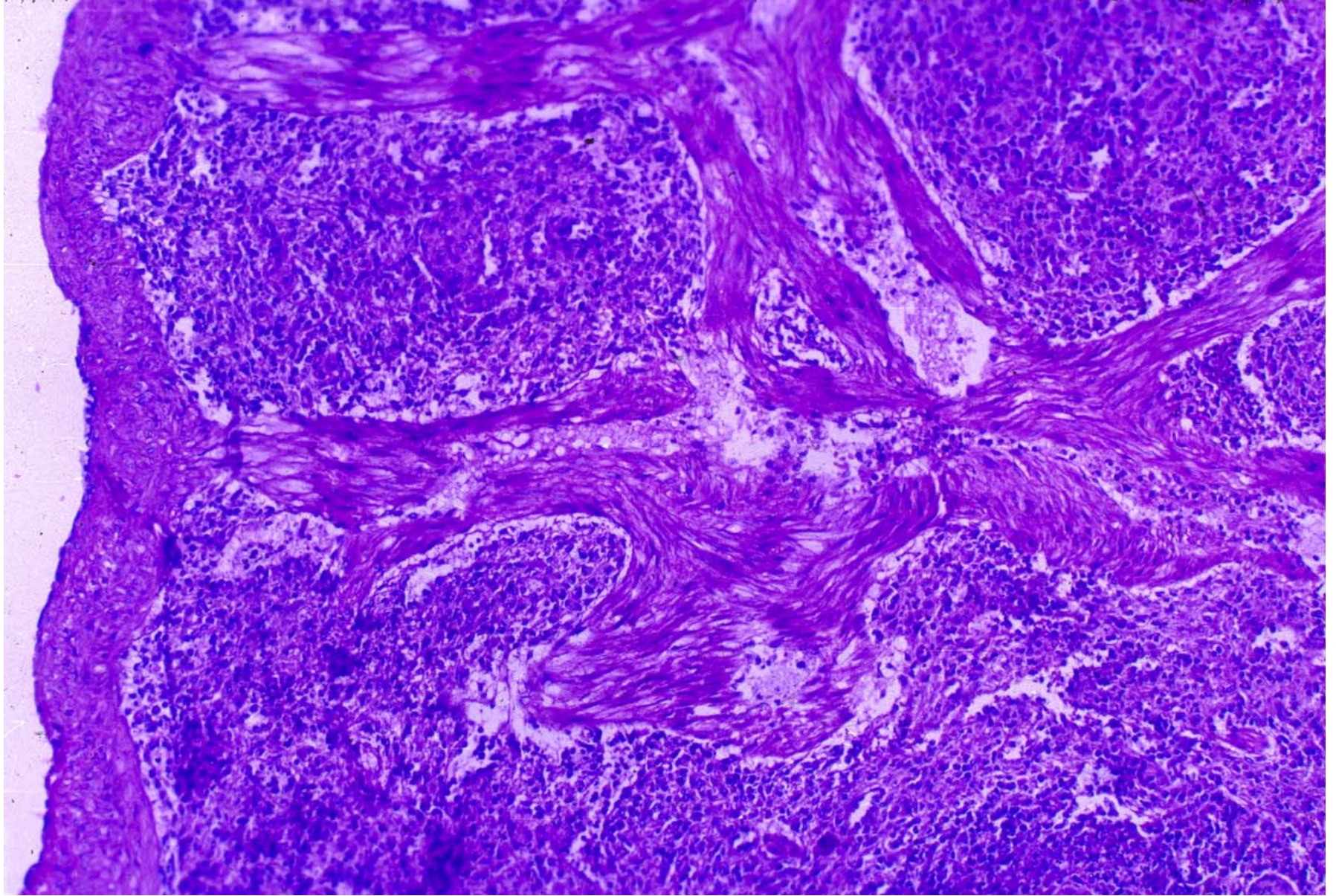




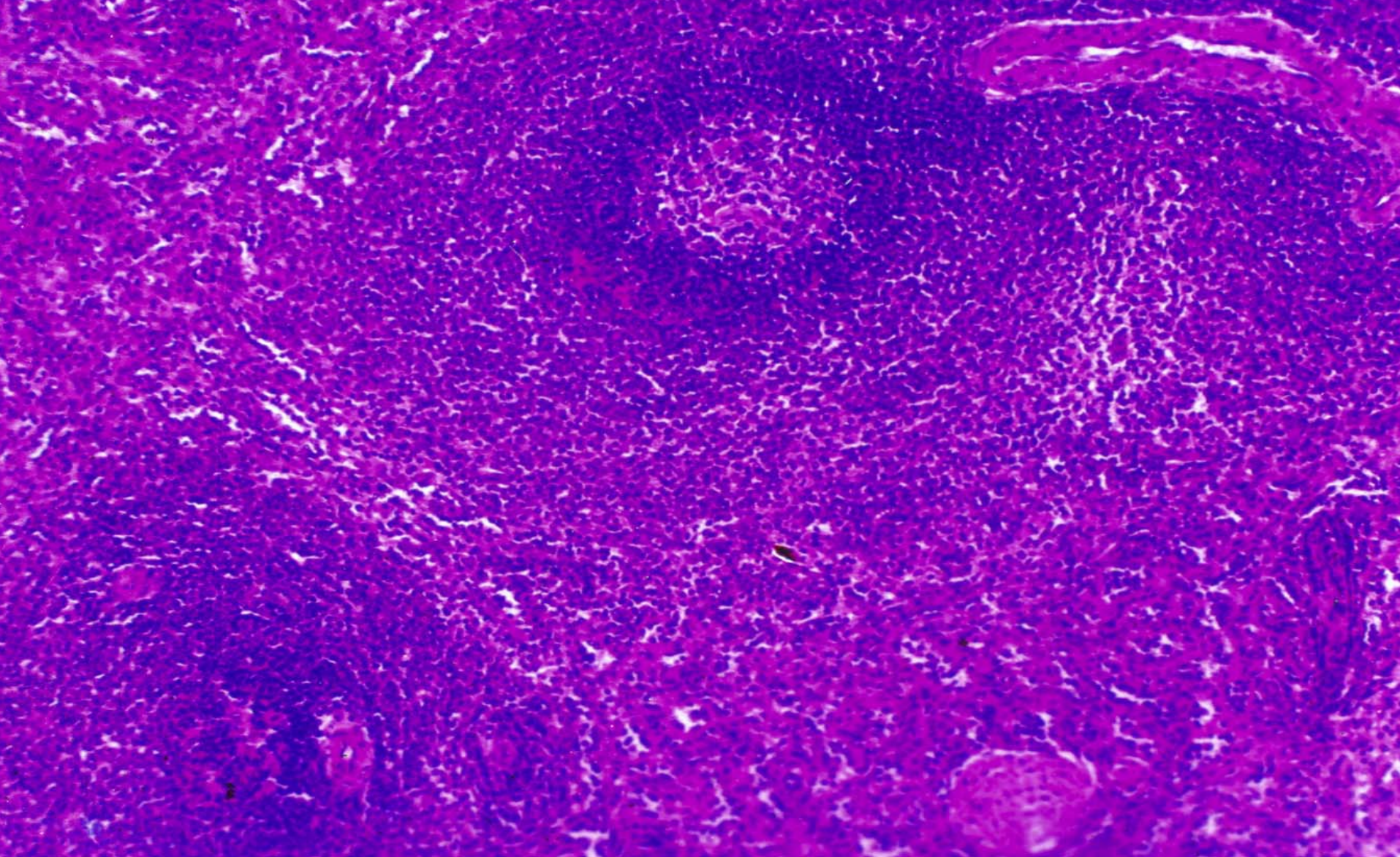
**Postcapillary venules**



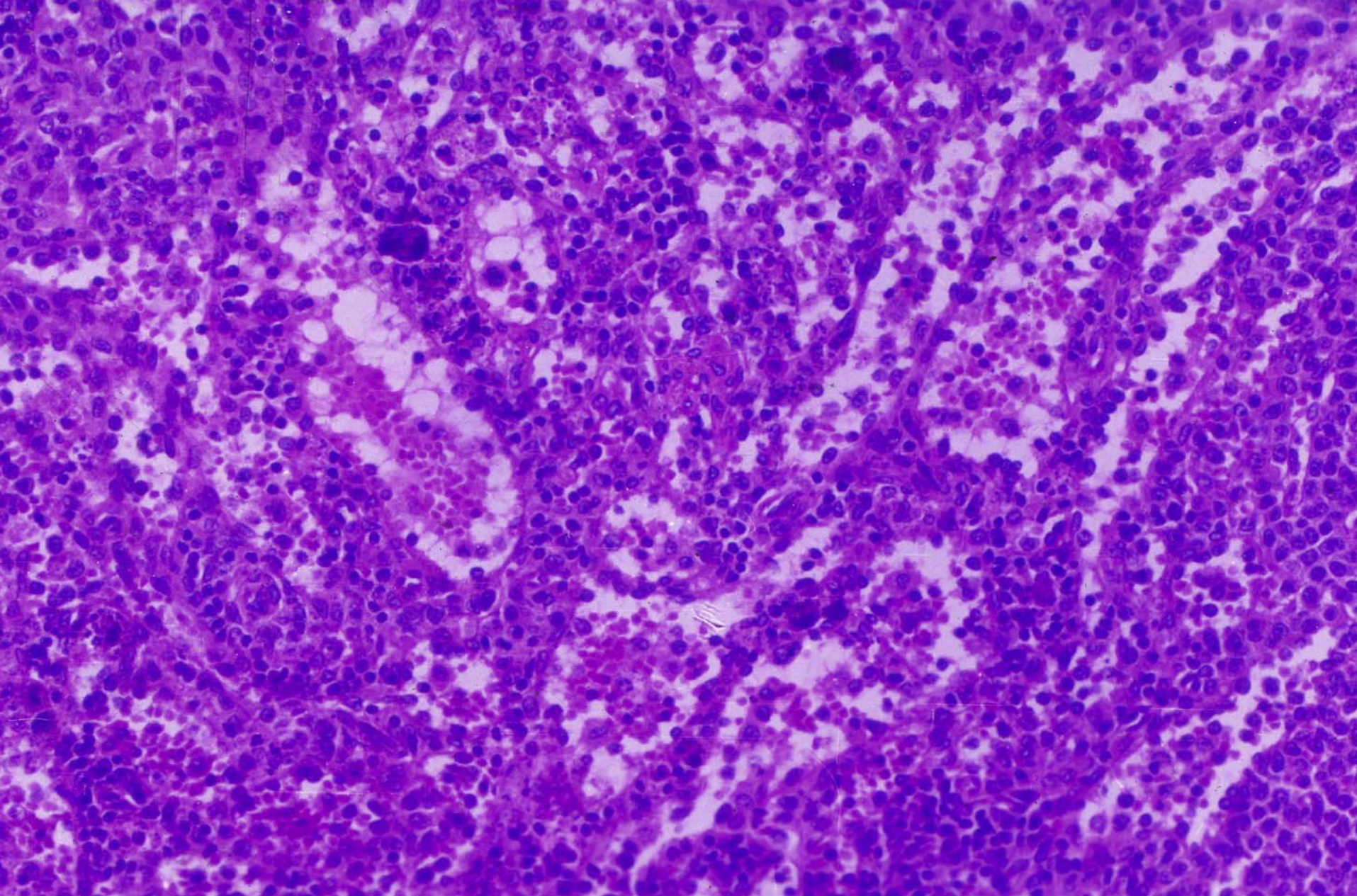
**spleen**



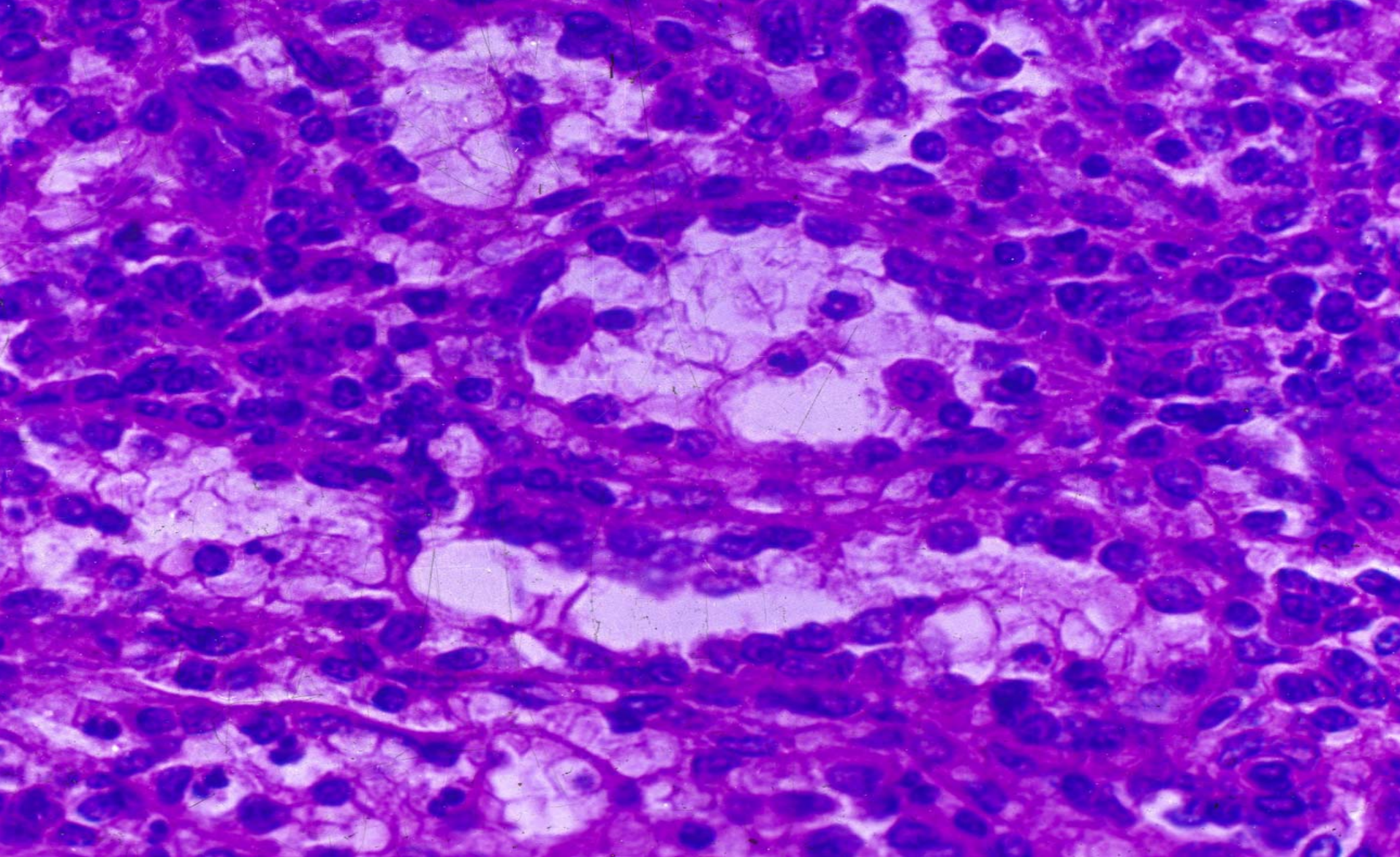
**trabecular**



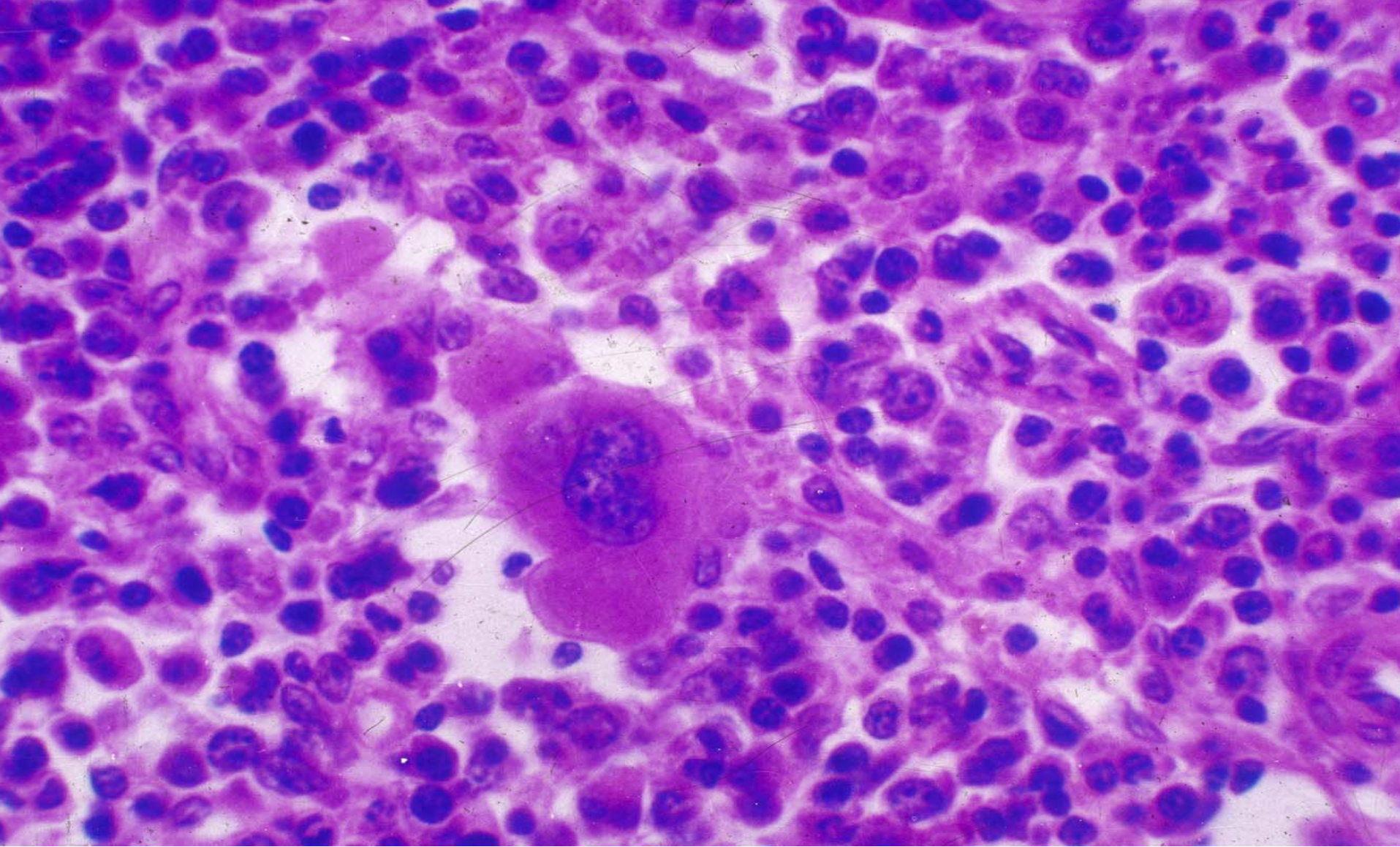
**Splenic corpuscle**



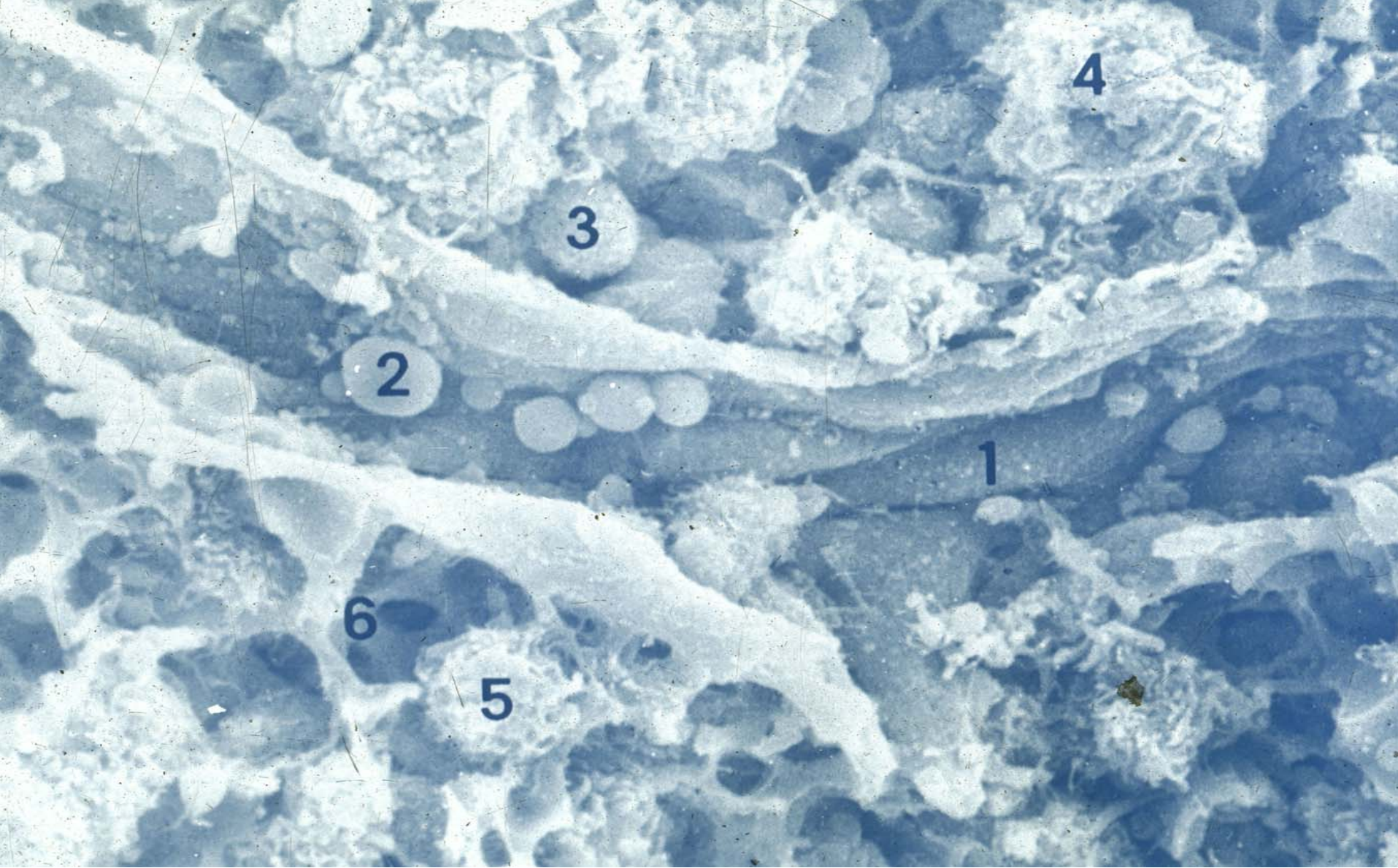
**Red pulp**



**Splenic cord and splenic sinus**

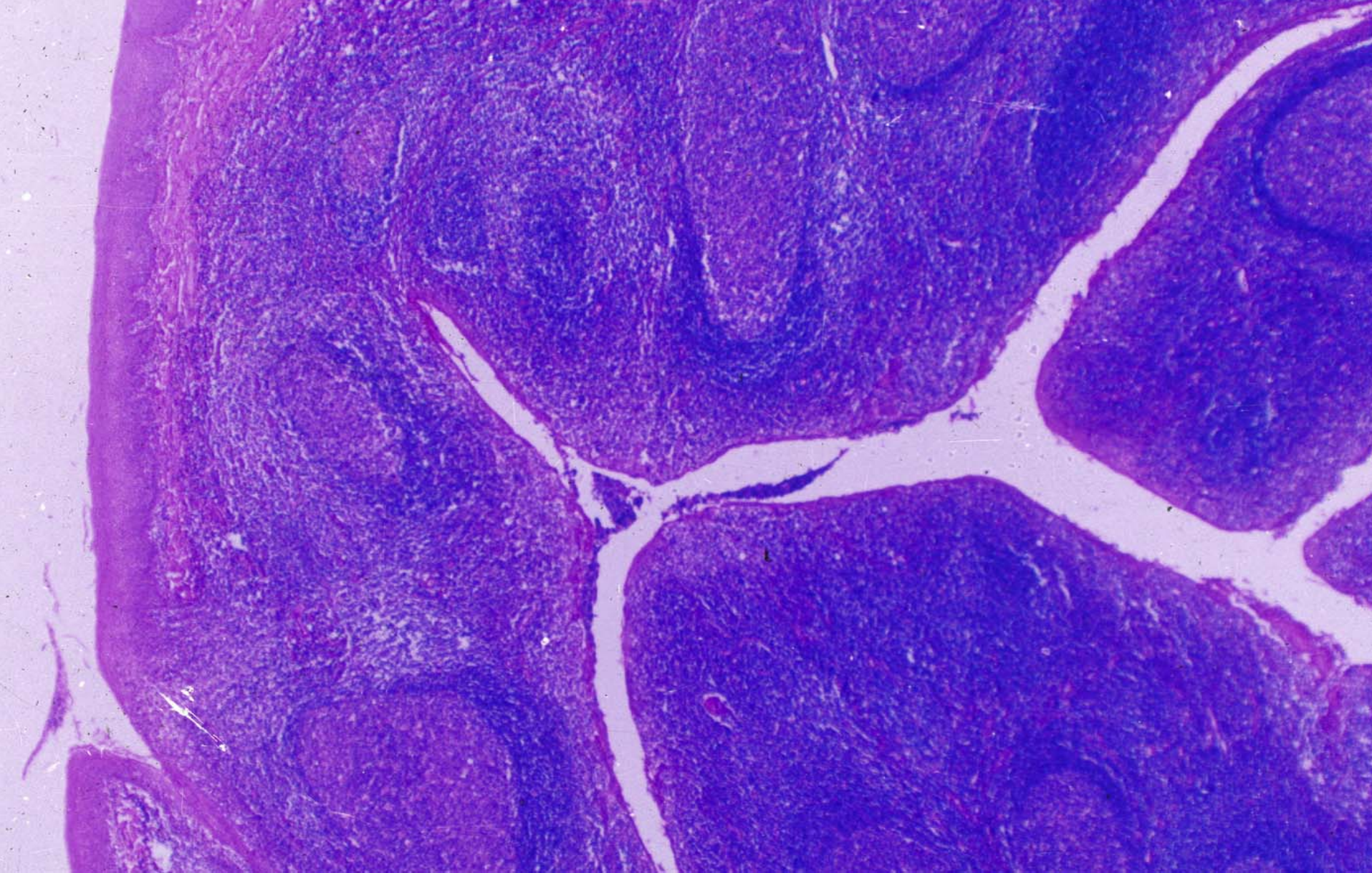


**macrophage**

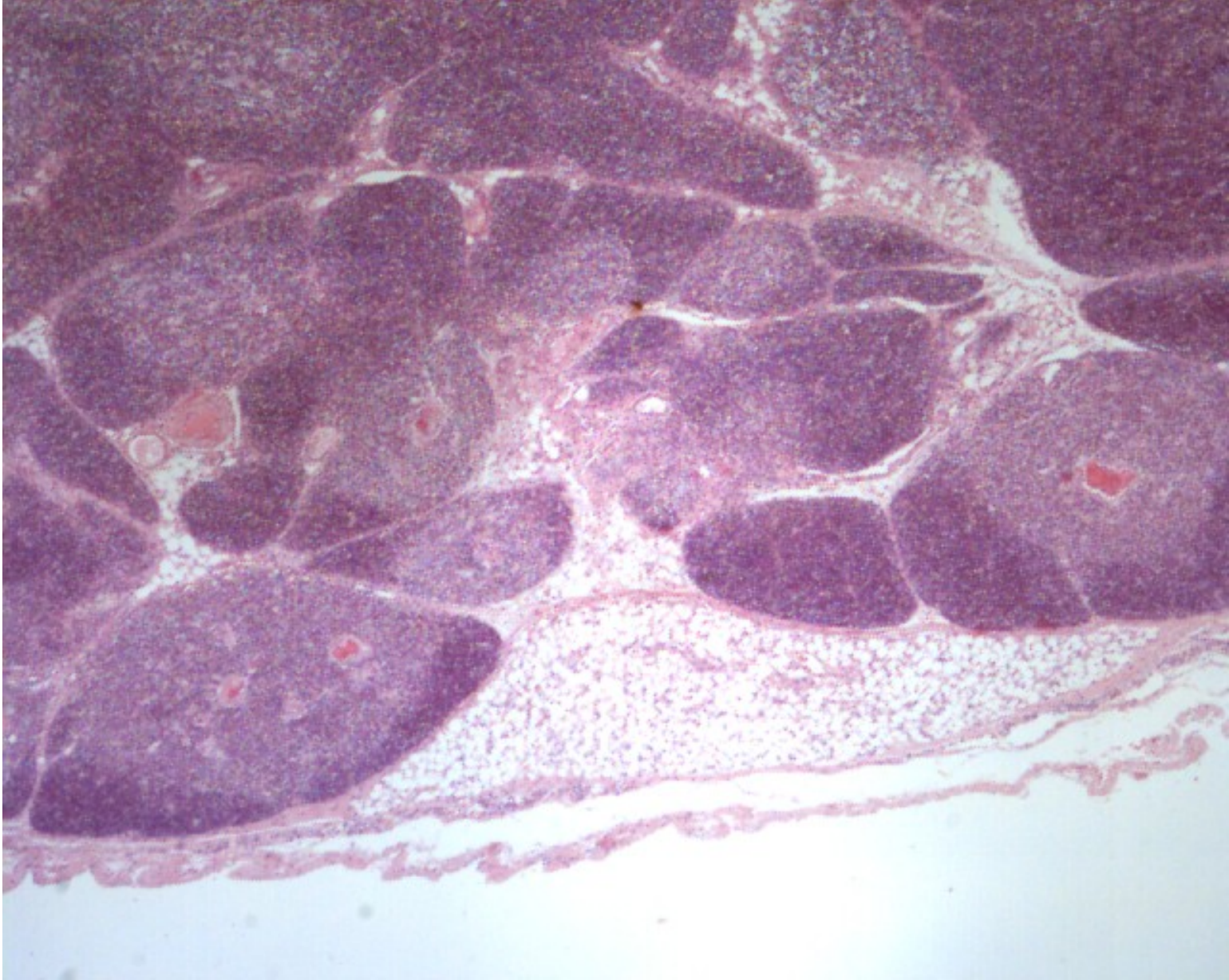


**Splenic sinus**

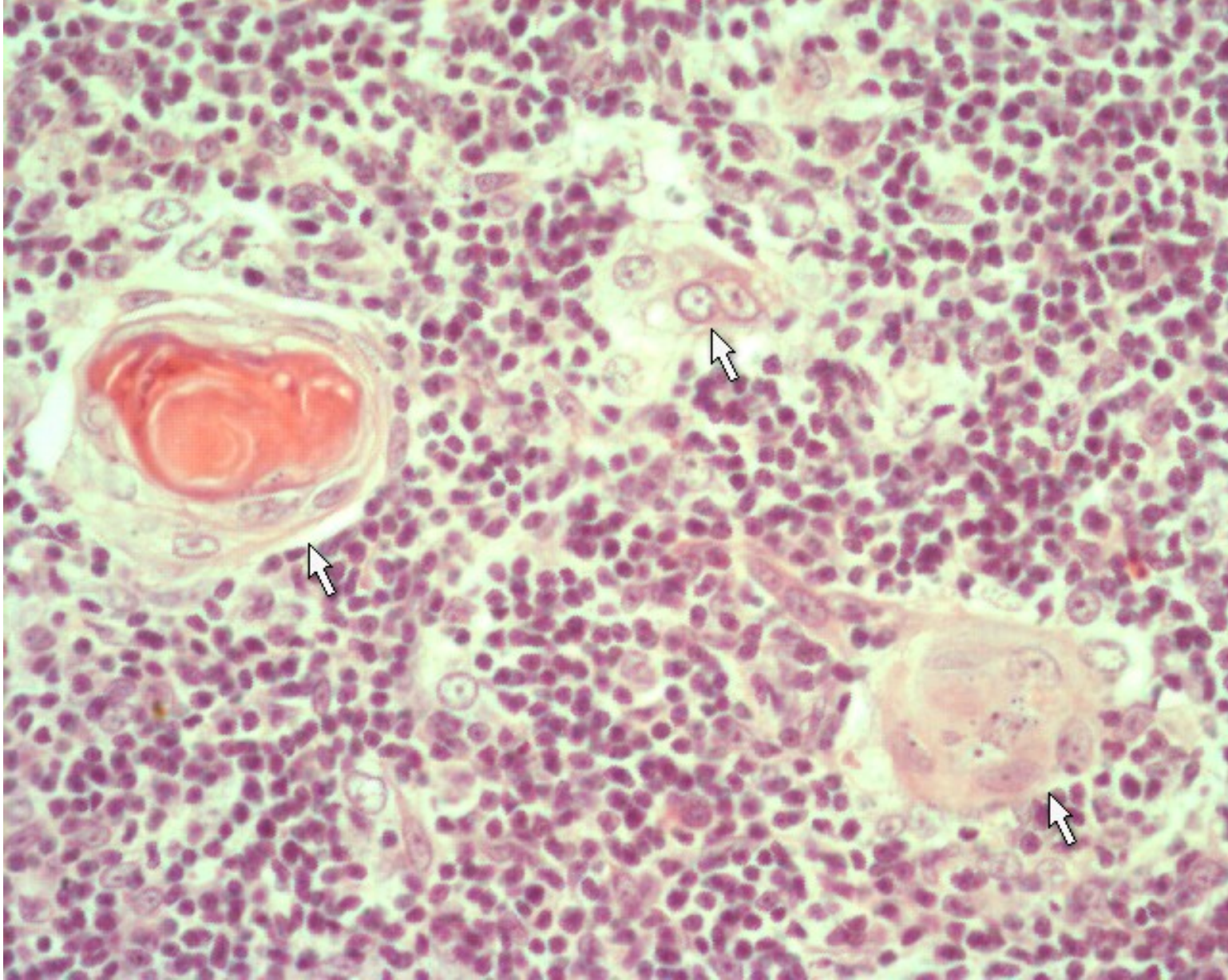




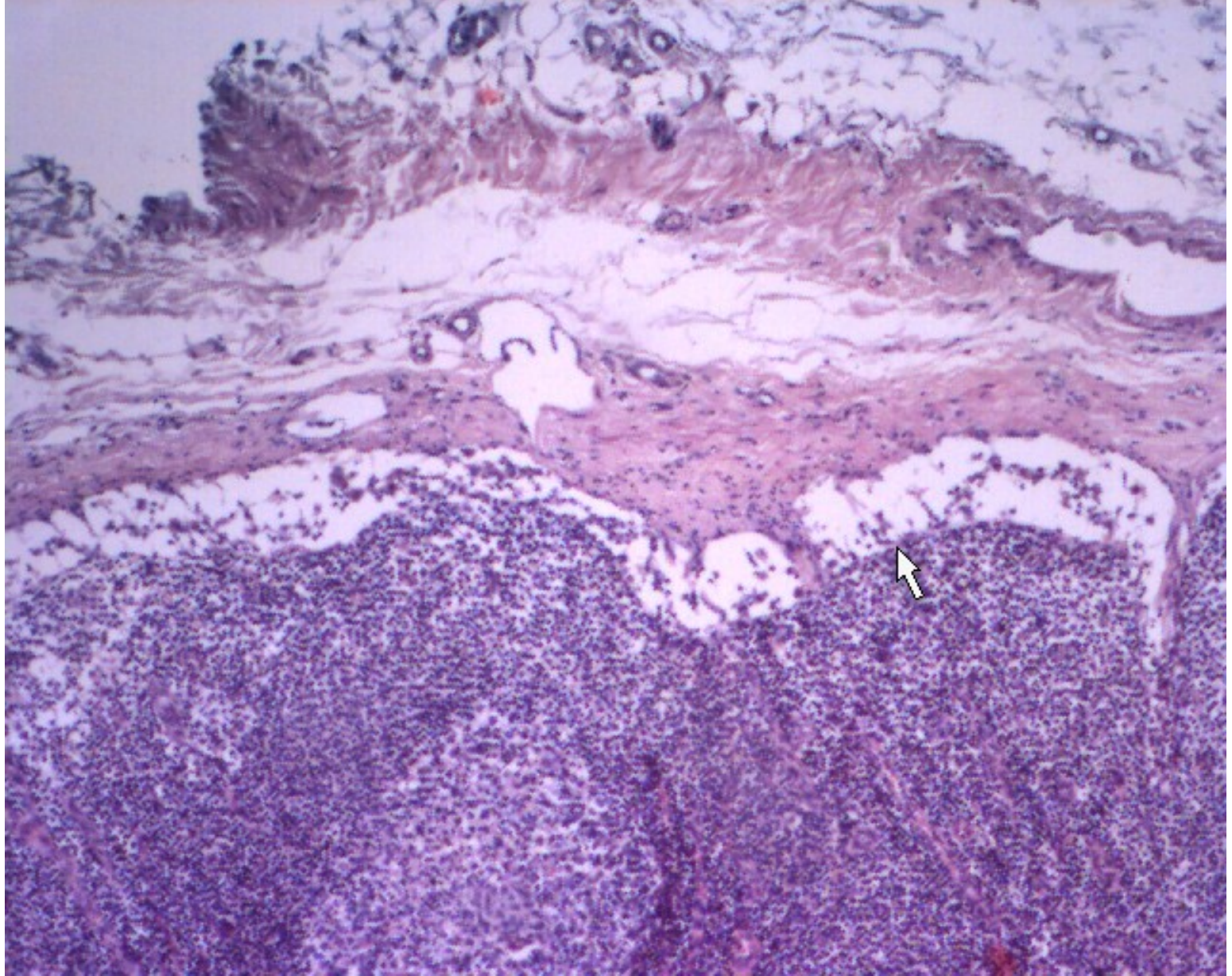
**tonsil**



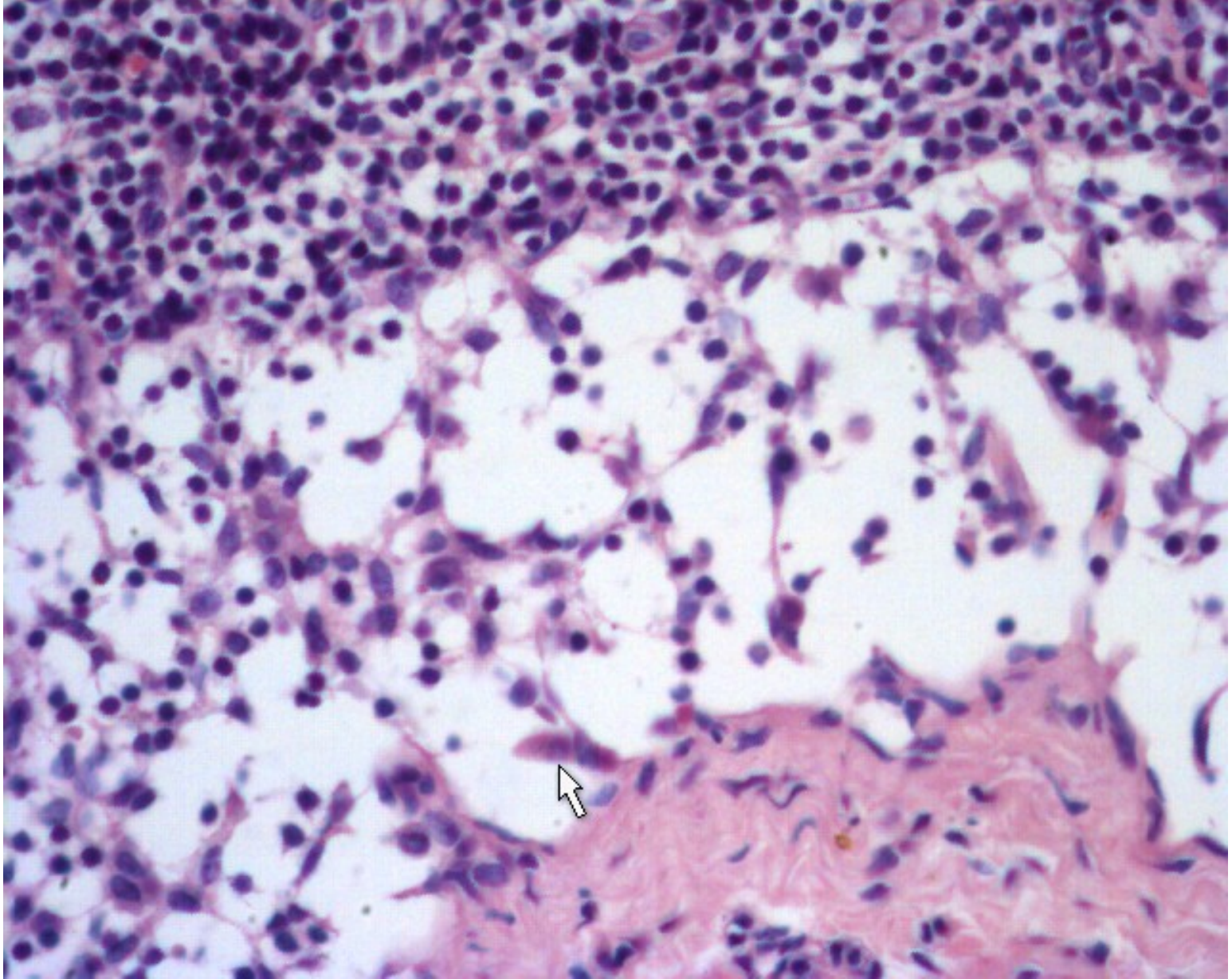
**thymus**



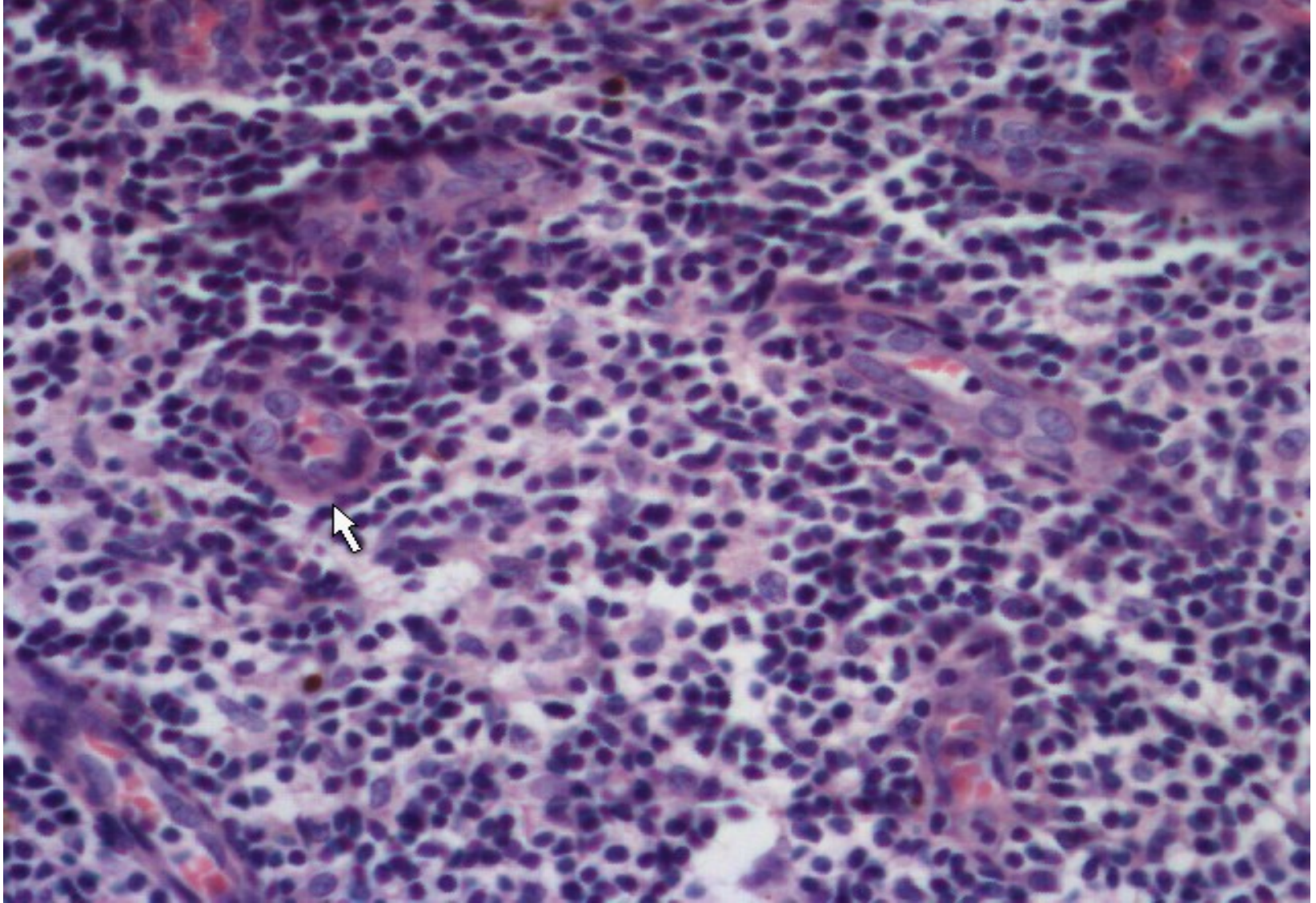
**Thymic corpuscle**



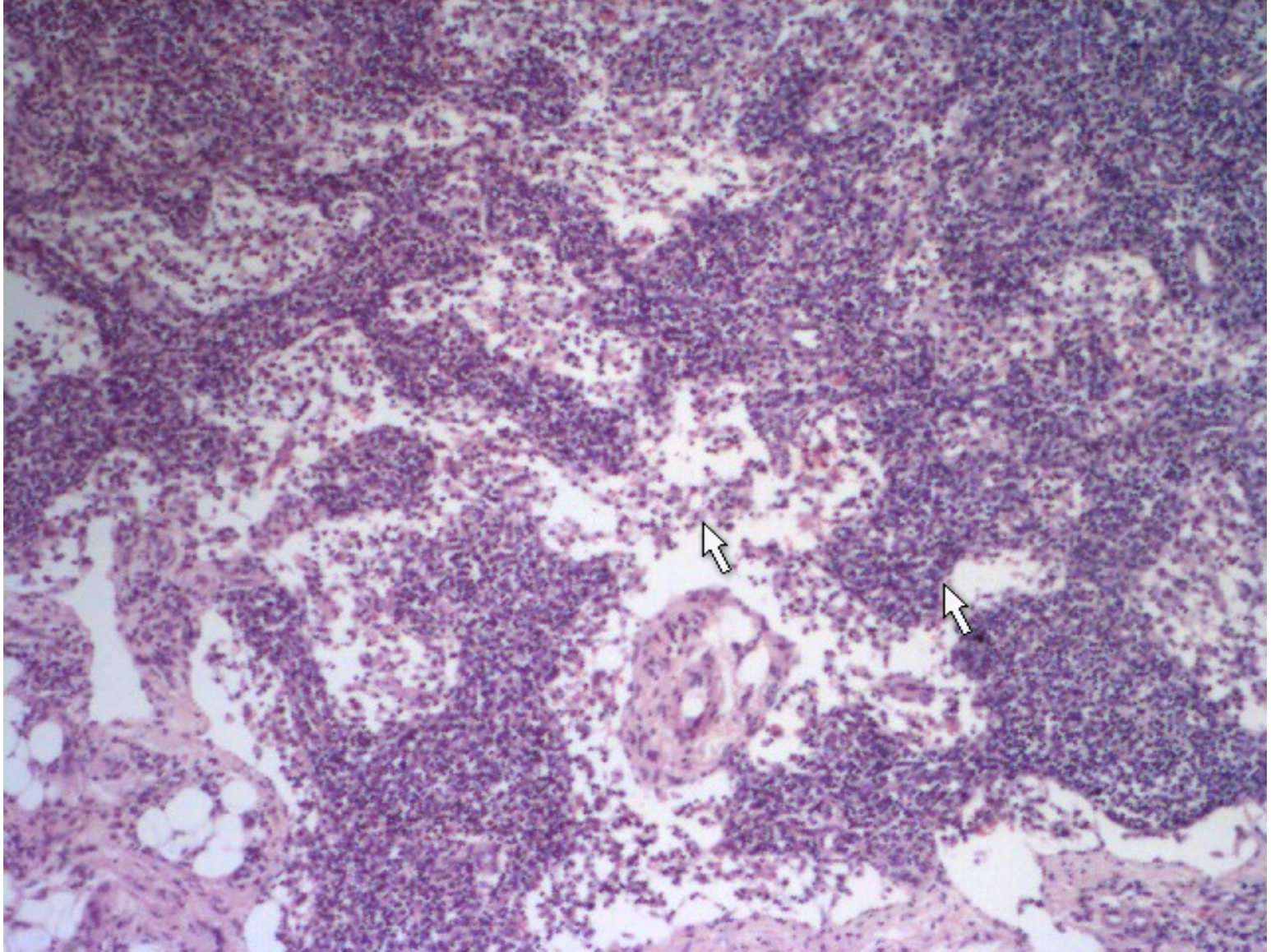
**Afferent lymphatic vessel**



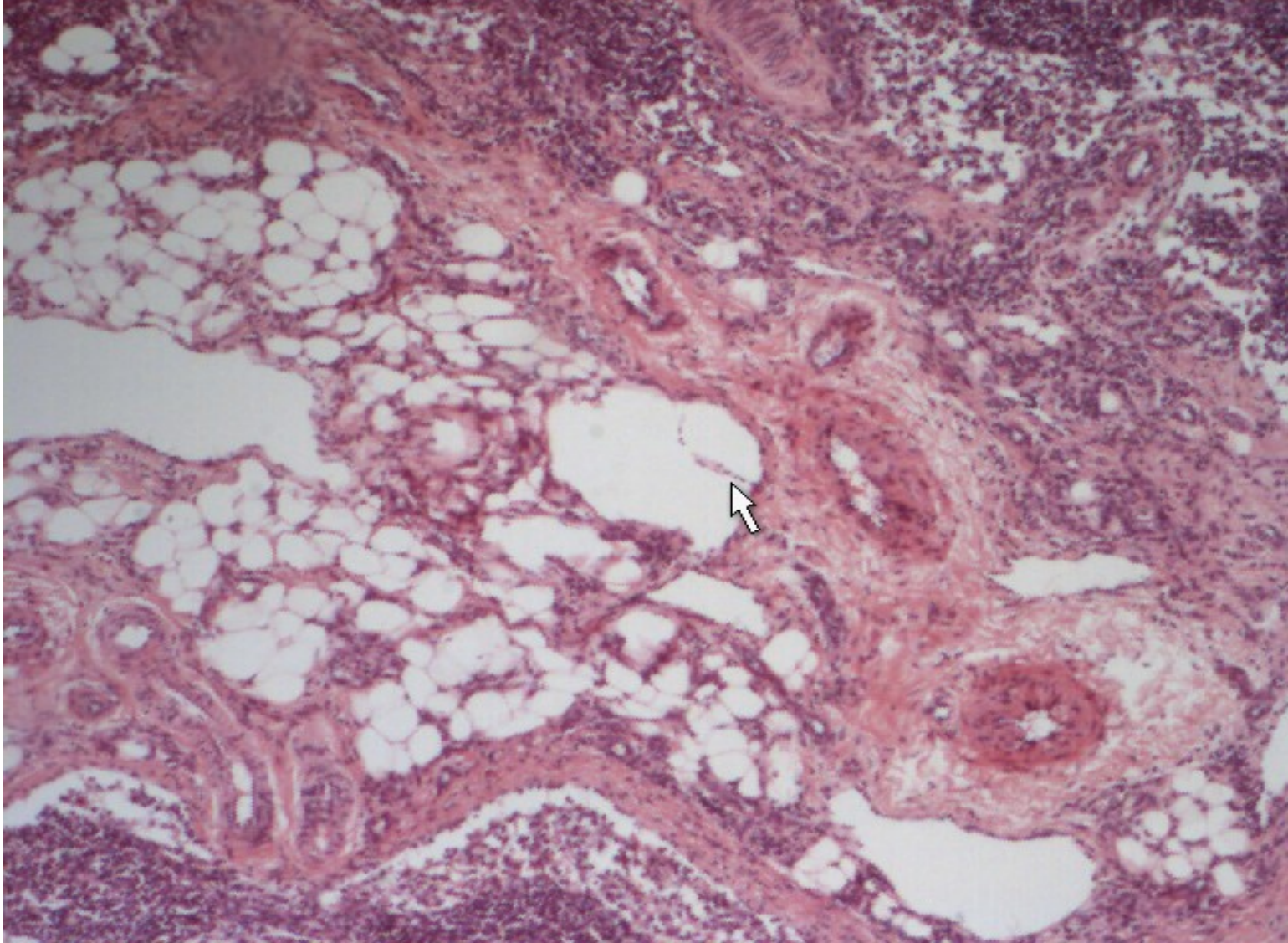
**Supcapsular sinus**



**Postcapillary venules**

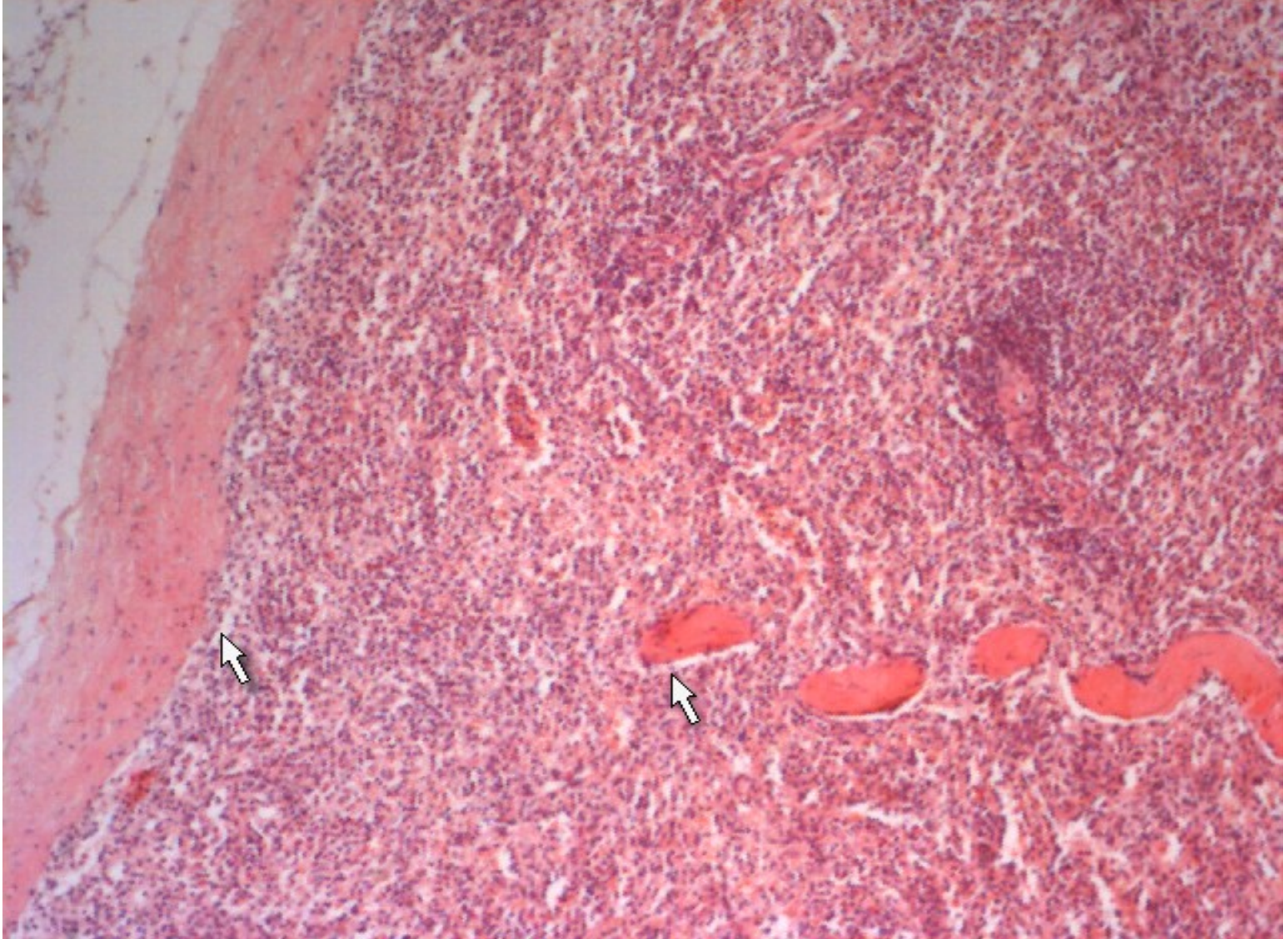


**medulla**

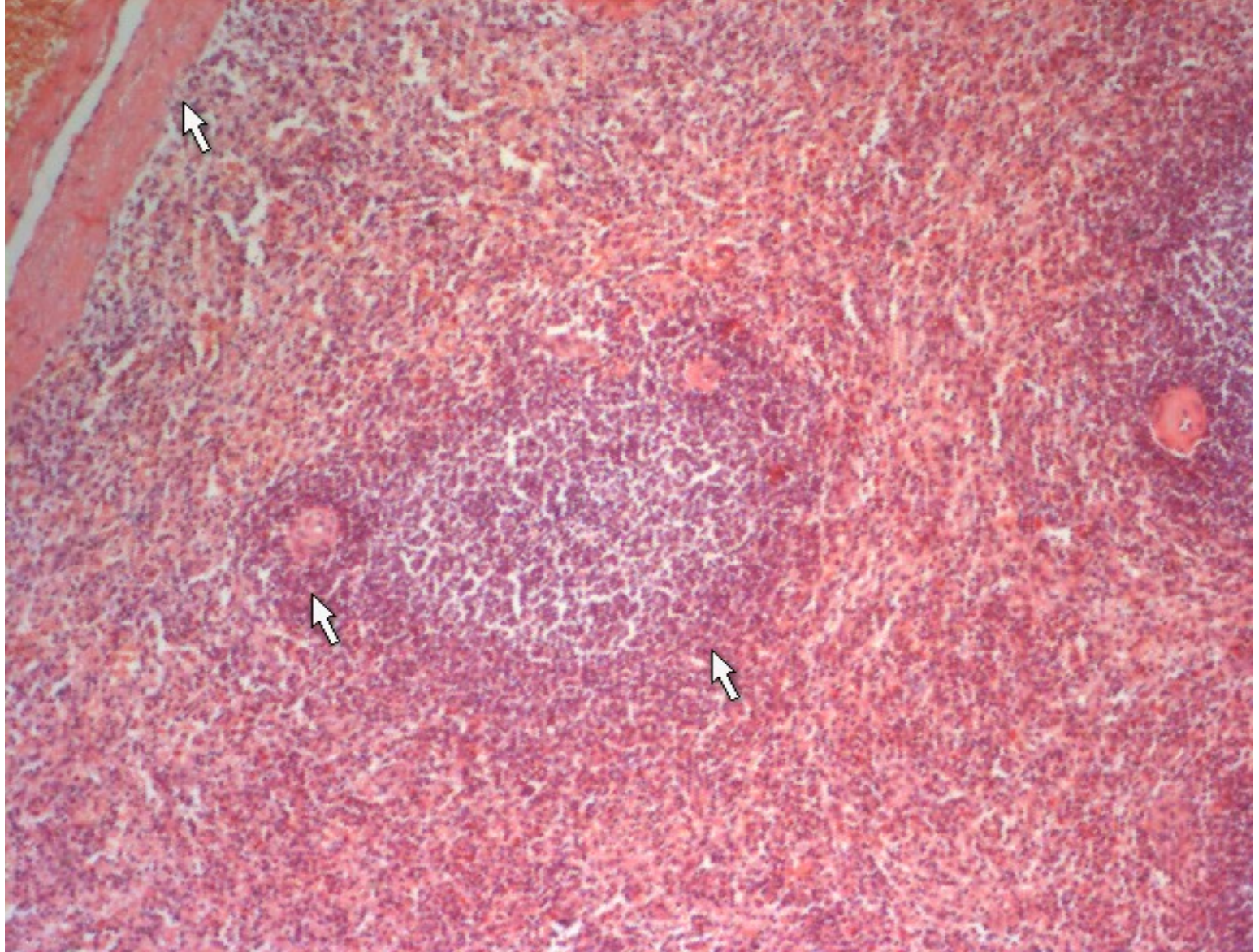


**hilus**

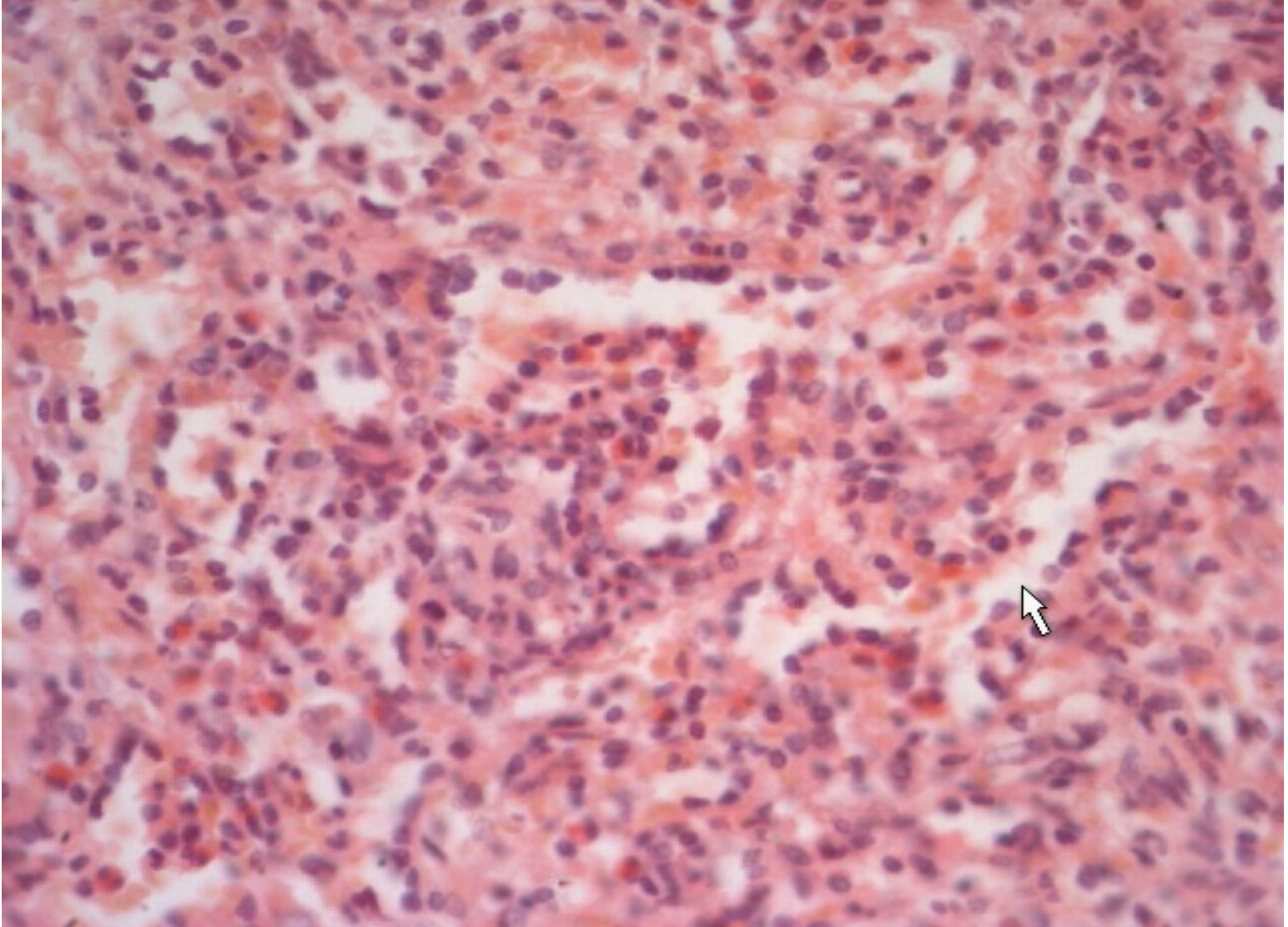




**trabecula**



**Splenic corpuscle**



**Splenic cord and splenic sinus**