

Female Reproductive System



Department of Histology and
Embryology of Jilin university

----Xue Hui

General description

Ovaries

Oviducts

uterus

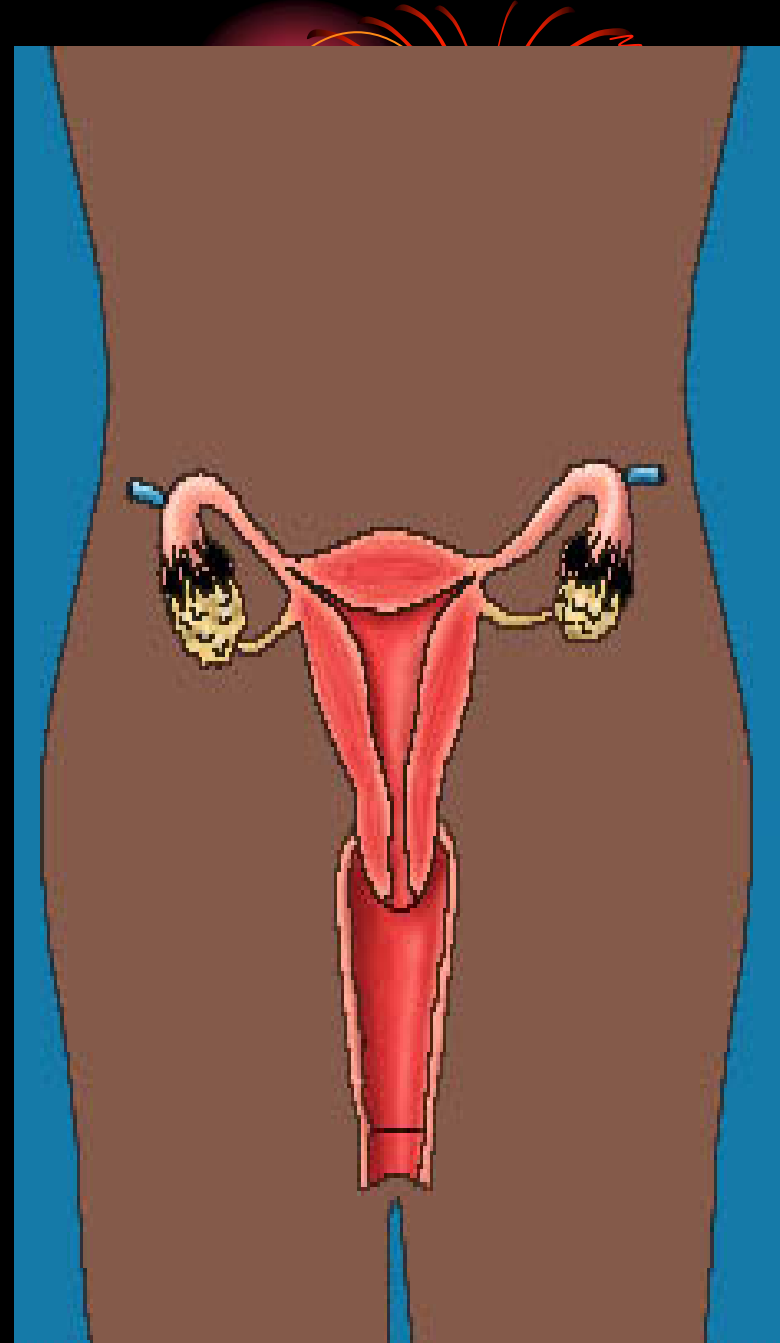
vagina

external genitalia

mammary glands

Functions:

produce oocytes, sexual hormones




I . Ovaries

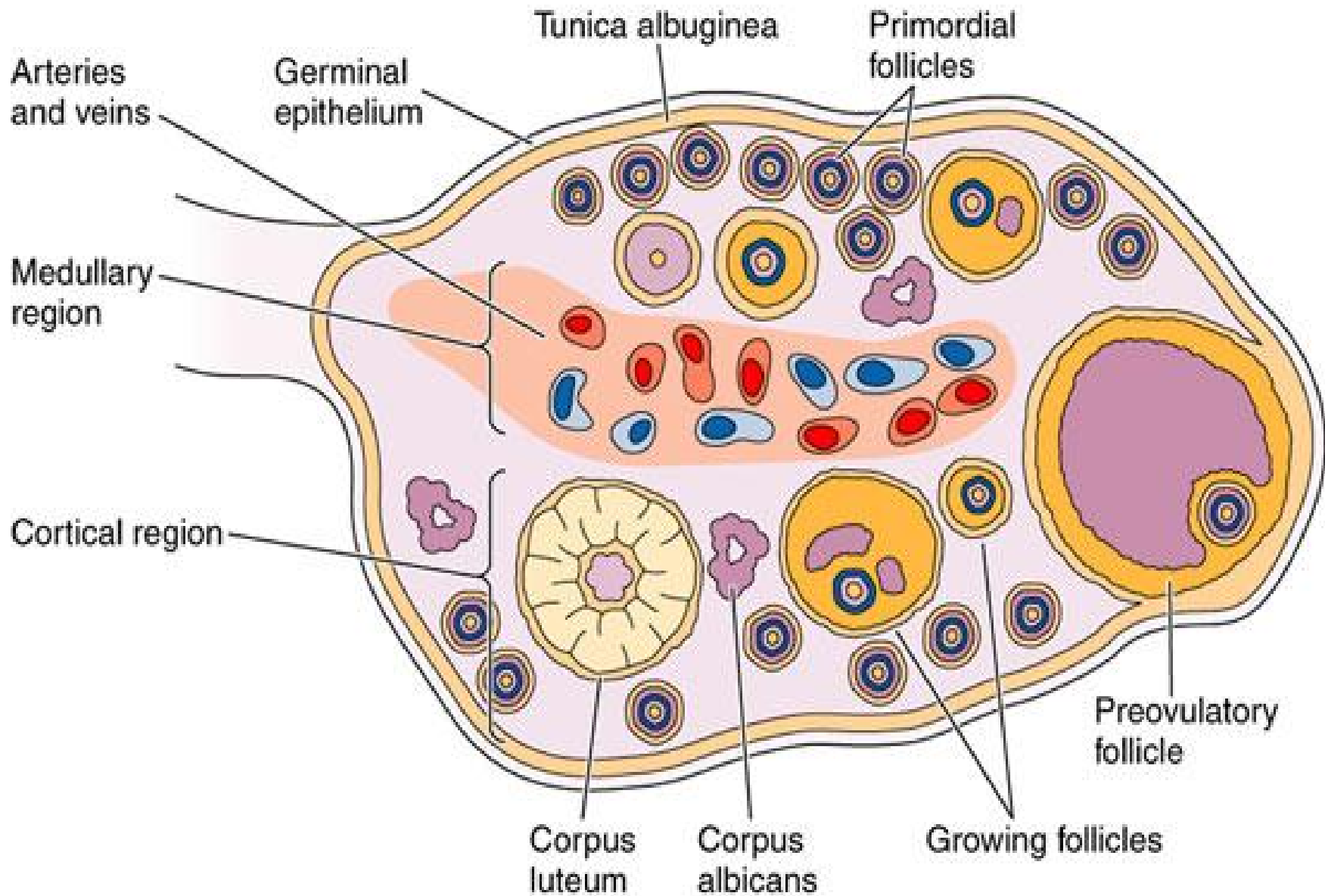
Superficial epithelium

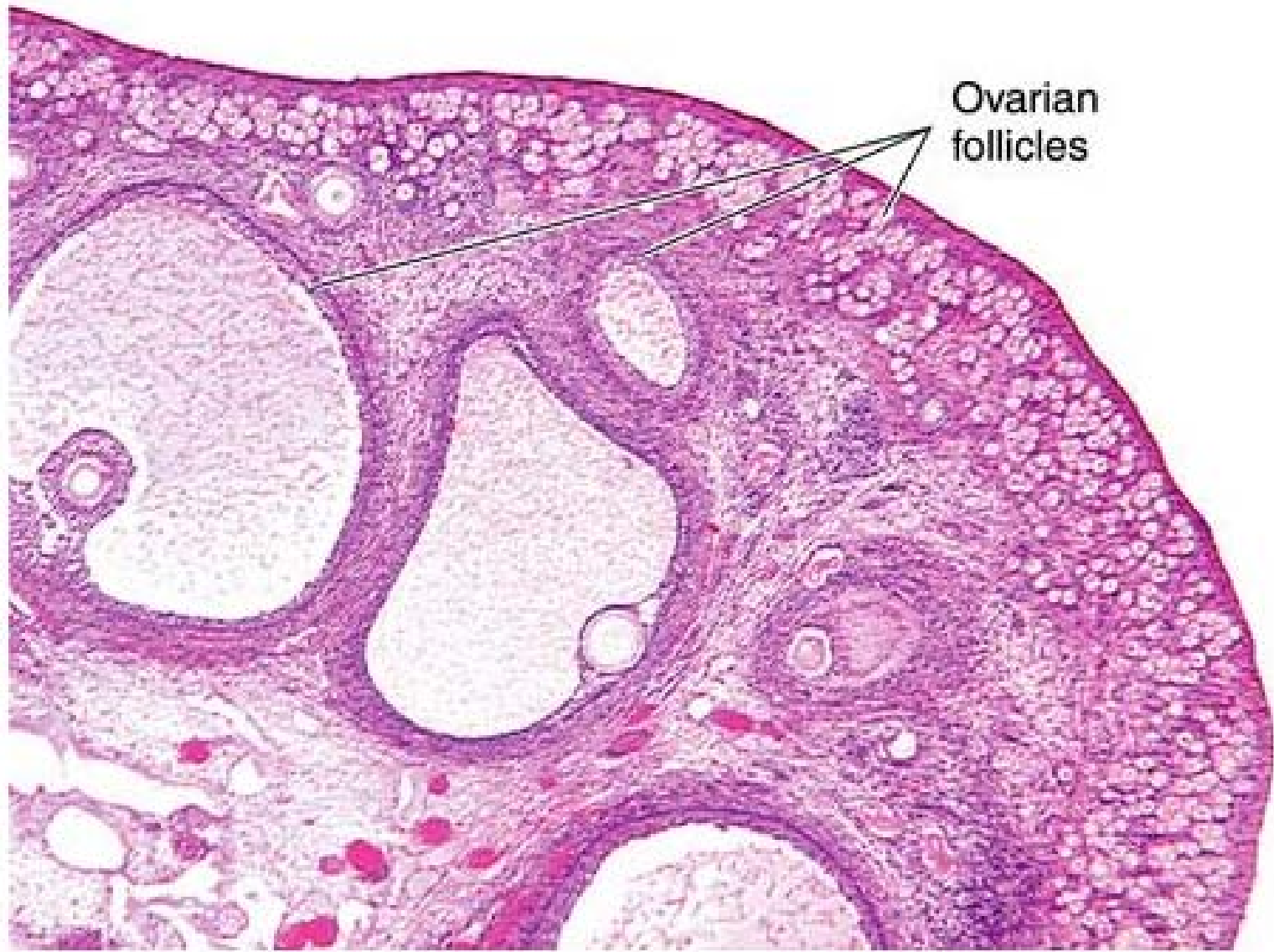
Tunica albuginea

parenchyma: Cortical region

Medullary region







Ovarian
follicles

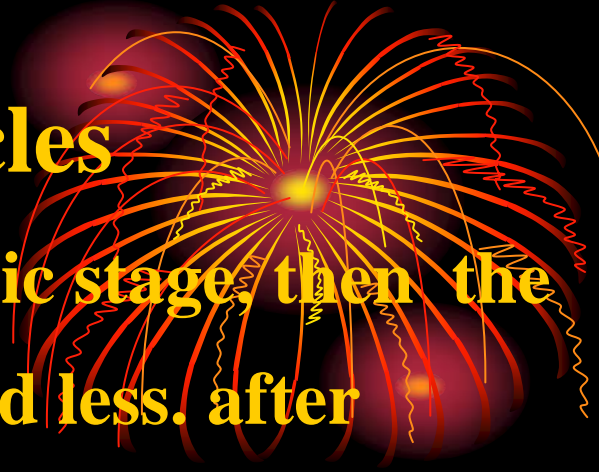Medullary
region

Cortical
region

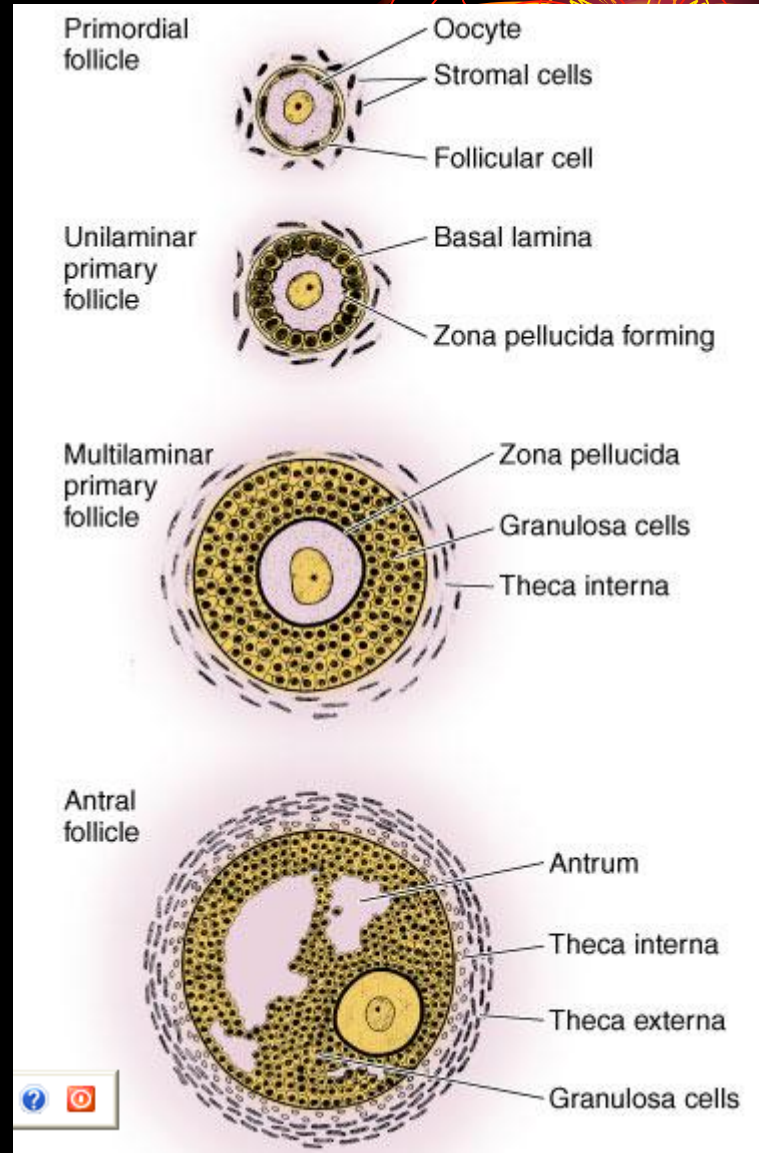
Development of follicles

● Follicles germinate from embryonic stage, then the number of them is becoming less and less. after puberty, generally only one oocyte is liberated by the ovaries in each menstrual cycle.

In the postmenopausal period, the ovaries stop to liberate oocytes. the development of the follicles make up of three stages: primordial follicles, growing follicles and mature follicles

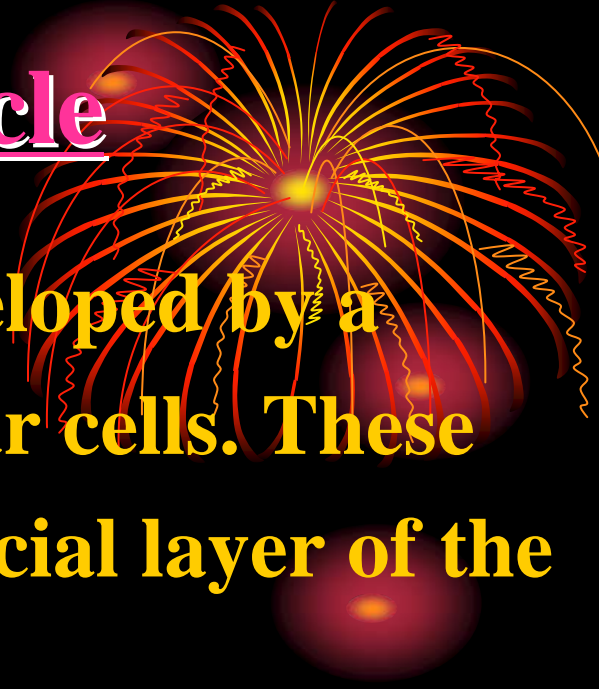

- **An ovarian follicle consists of an oocyte surrounded by one or more layers of follicular cells, or granulosa cells.**

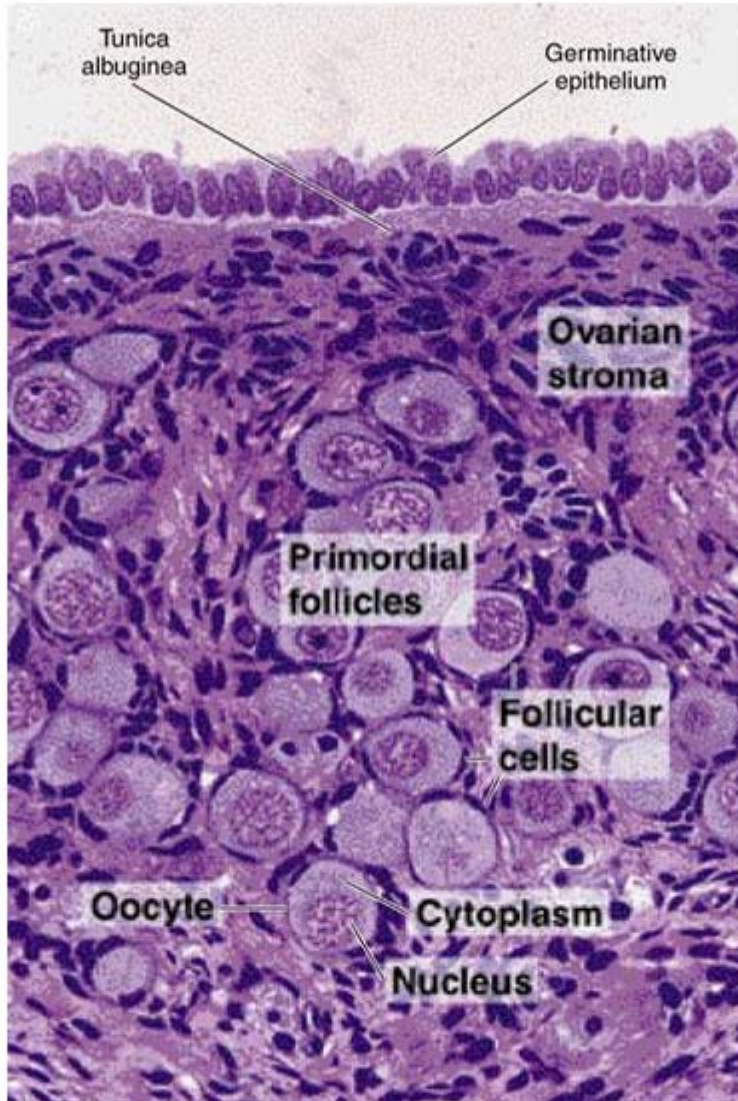
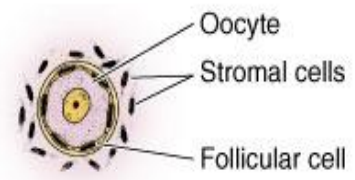


1. primordial follicle

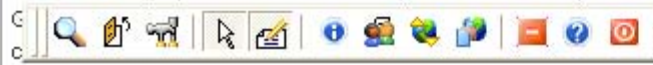- **consist of a primary oocyte enveloped by a single layer of flattened follicular cells. These follicles are found in the superficial layer of the cortical region.**
- **The oocyte is a spherical cell. Its nucleus is large and has a large nucleolus. The organelles in the cytoplasm tend to form a clump adjacent to the nucleus.**
- **These cells are in the first prophase of meiosis.**



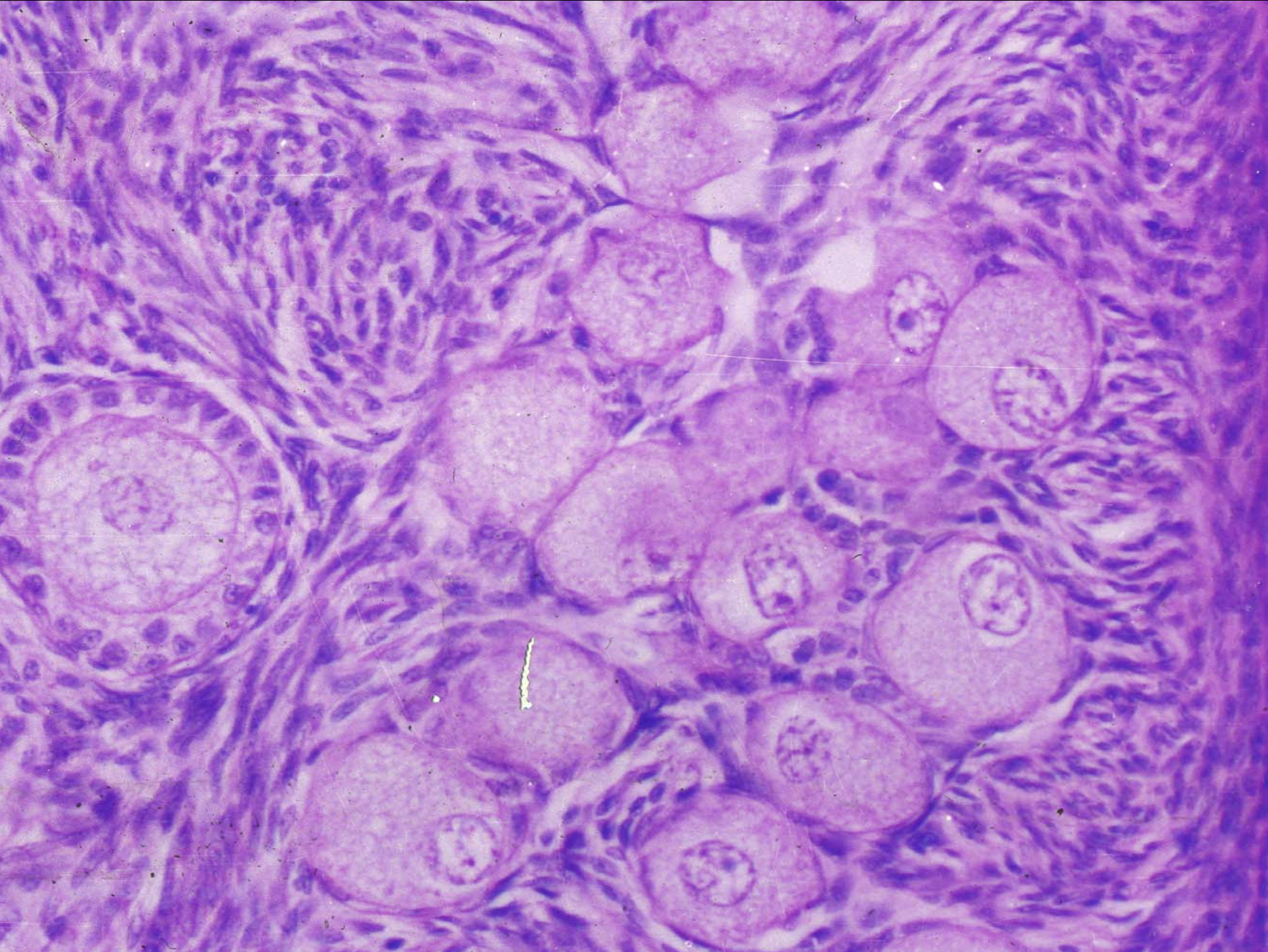
Primordial follicle



Photomicrograph of the cortical region of an ovary. The ovary is surrounded by the germinal epithelium and by the tunica albuginea.



surrounded by a layer of flat follicular cells, are present in the ovarian
tion.



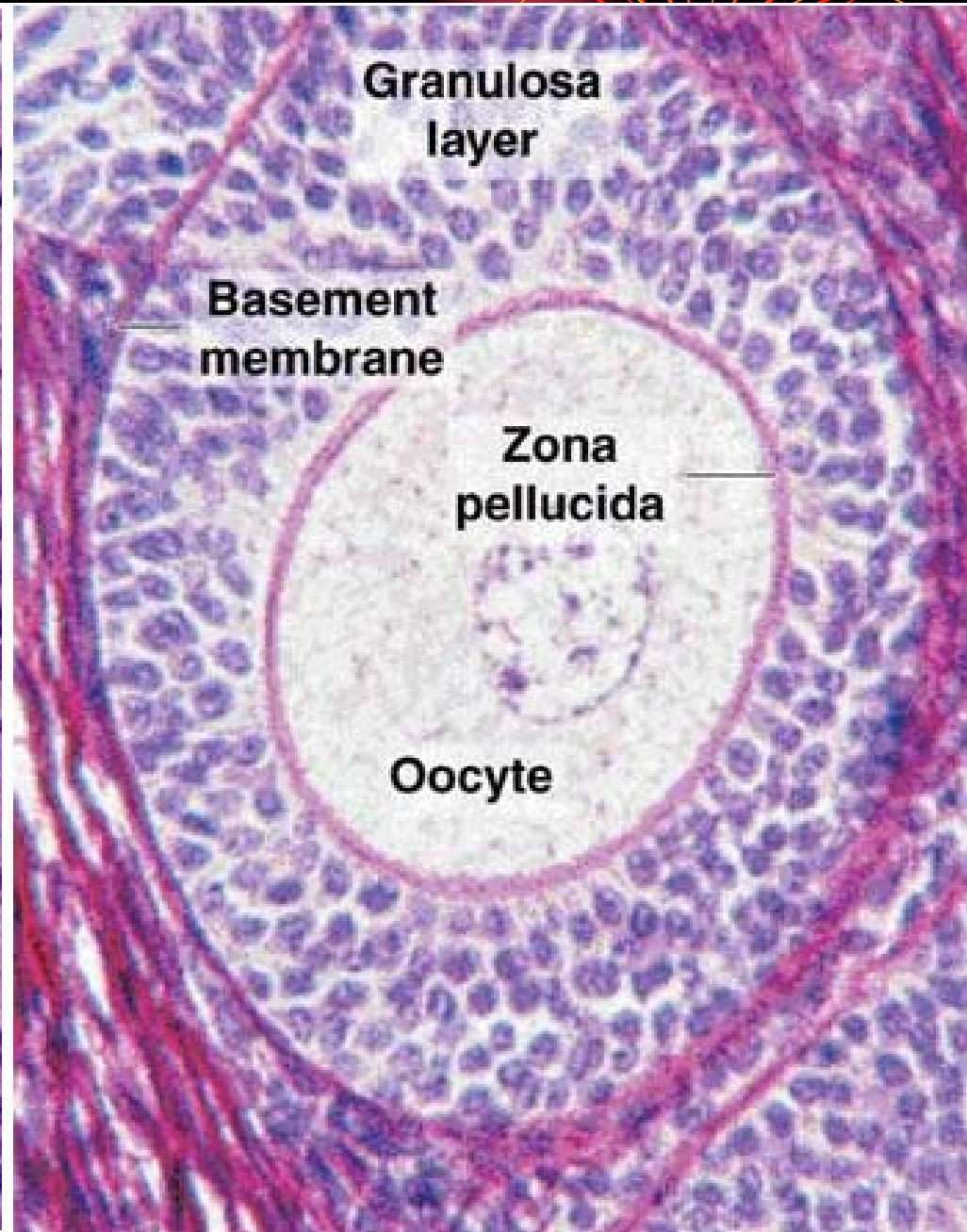
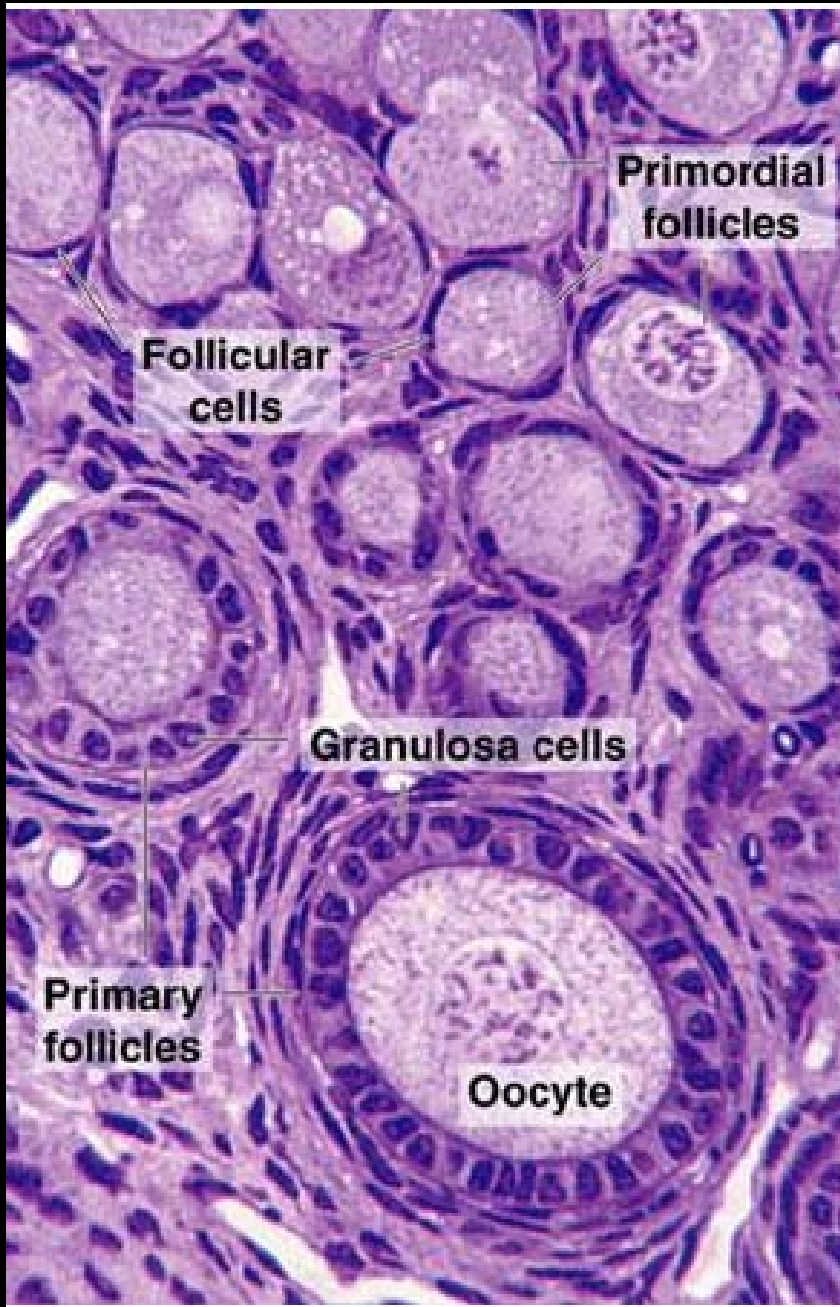
2. growing follicle



primary follicle

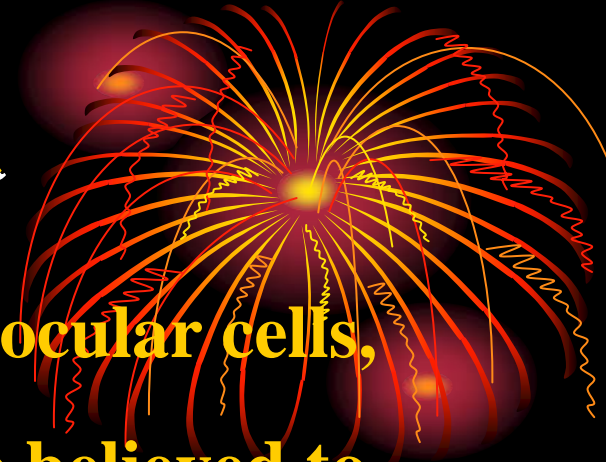The primary follicle is the first morphological stage that marks the onset of follicular maturation. The previously flattened cells surrounding the oocyte now form a cuboidal or columnar epithelium surrounding the oocyte. Their cytoplasm may have a granular appearance, and they are for this reason also called granulosa cells. The continued proliferation of these cells will result in the formation of a stratified epithelium surrounding the oocyte. The zona pellucida becomes visible.


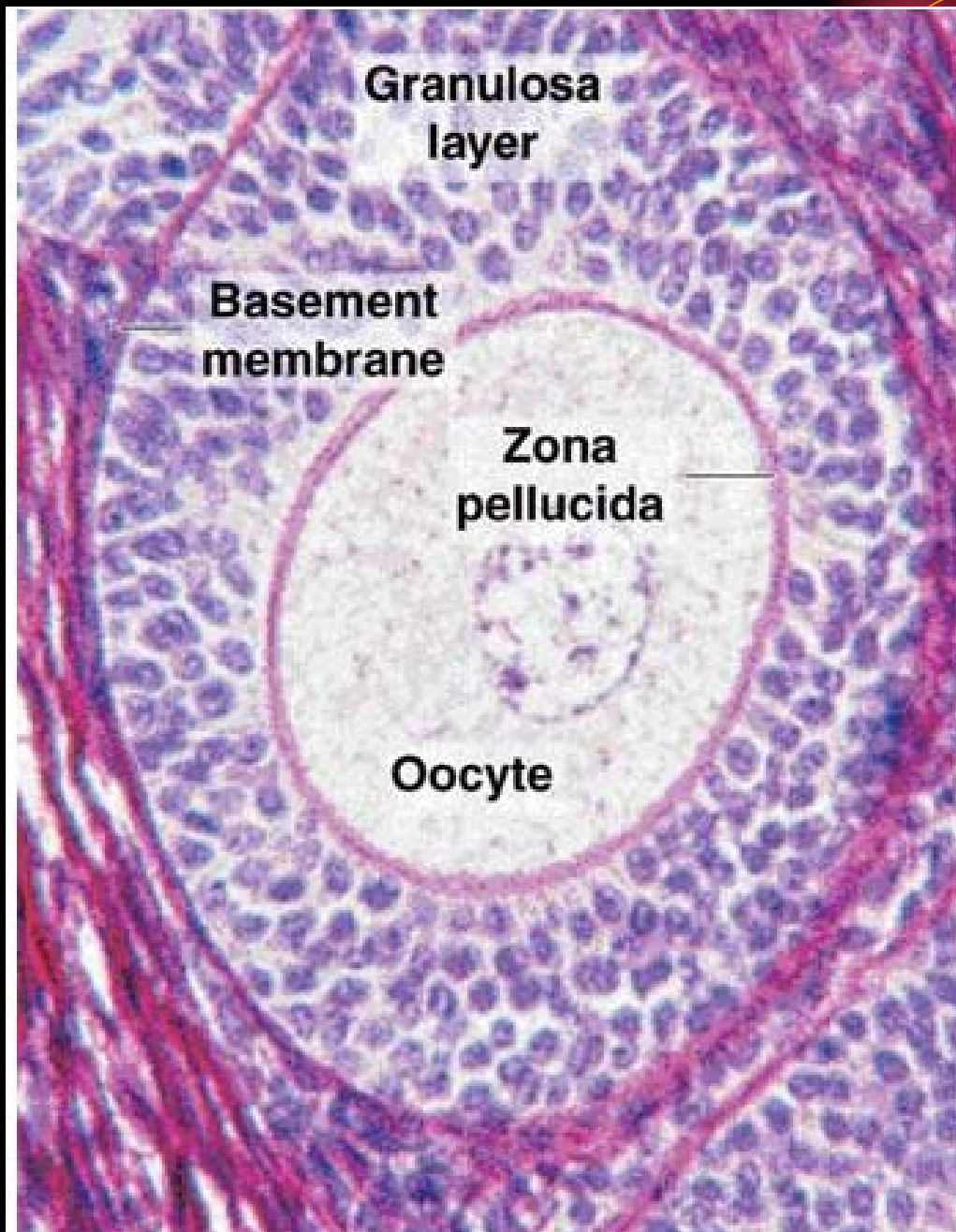
Parenchymal cells of the ovary surrounding the growing follicle become organised in concentric sheaths, the theca folliculi.

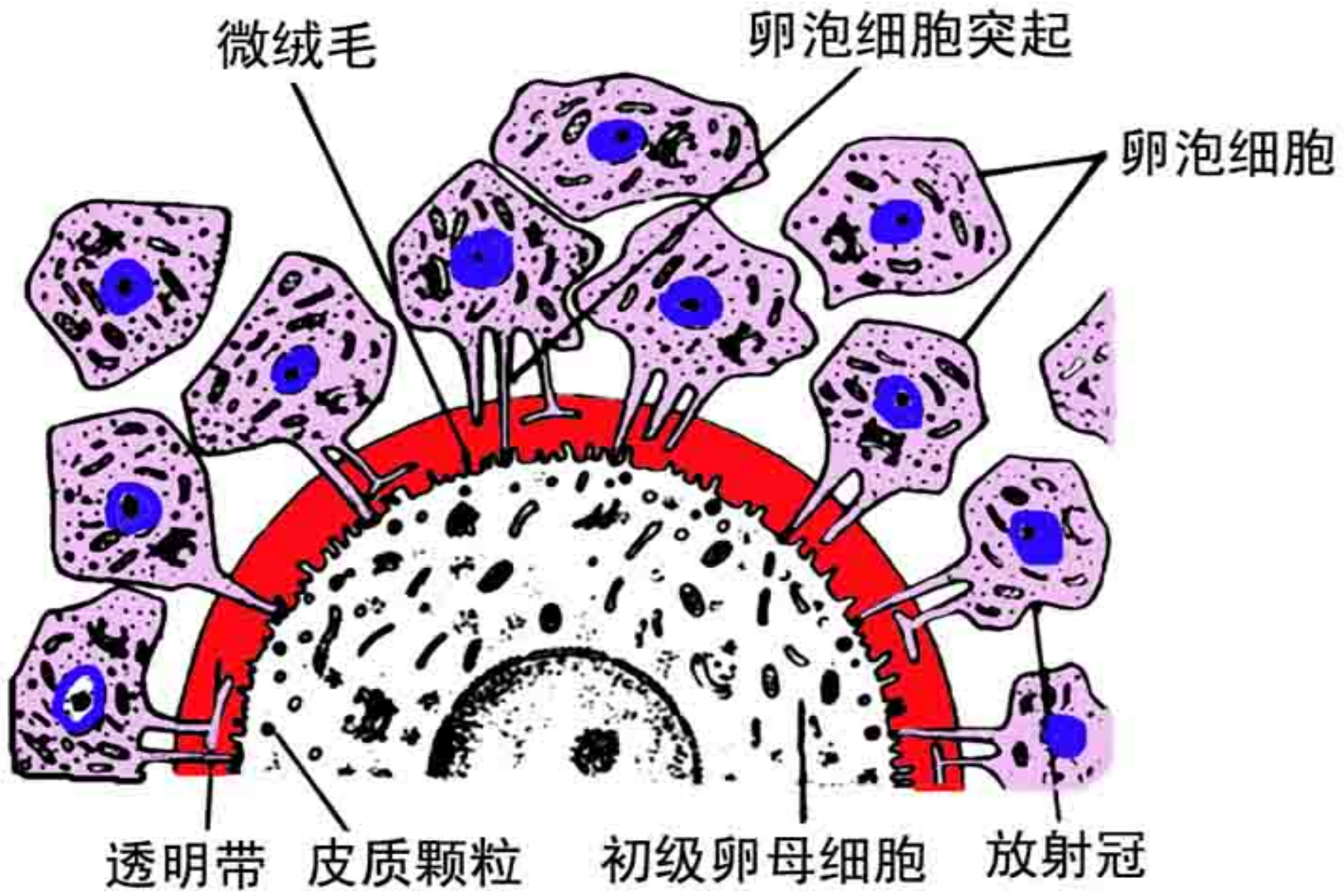


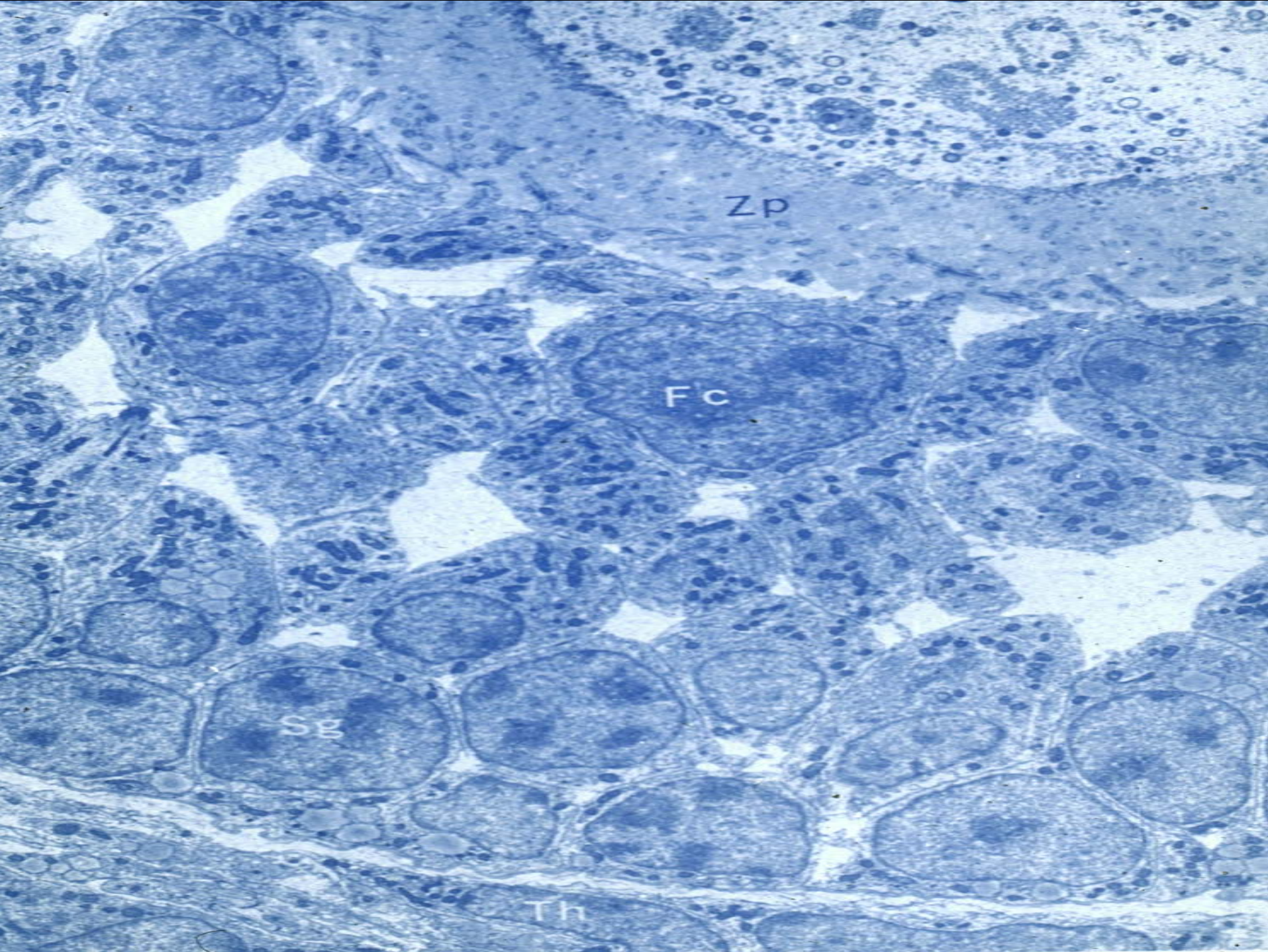
zona pellucida

**Is situated between the oocyte and follicular cells,
Both the oocyte and follicular cells are believed to
contribute to the synthesis of the zona pellucida. It is
composed of at least 3 glycoproteins . Filopodia of
follicular cells and microvilli of the oocyte penetrate
the zona pellucida and make contact with one
another via gap junctions.**







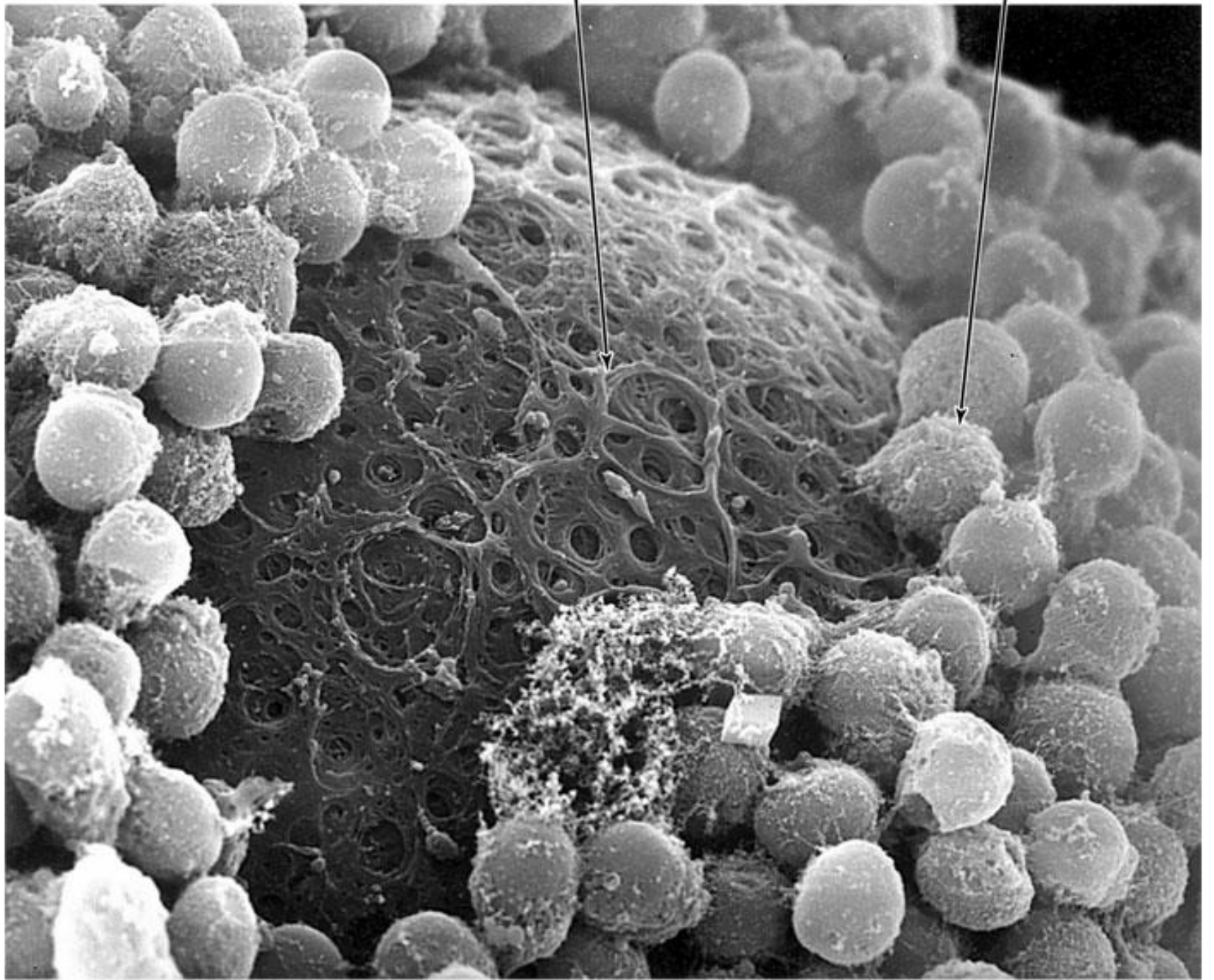


Zp

Fc

Tg


Th

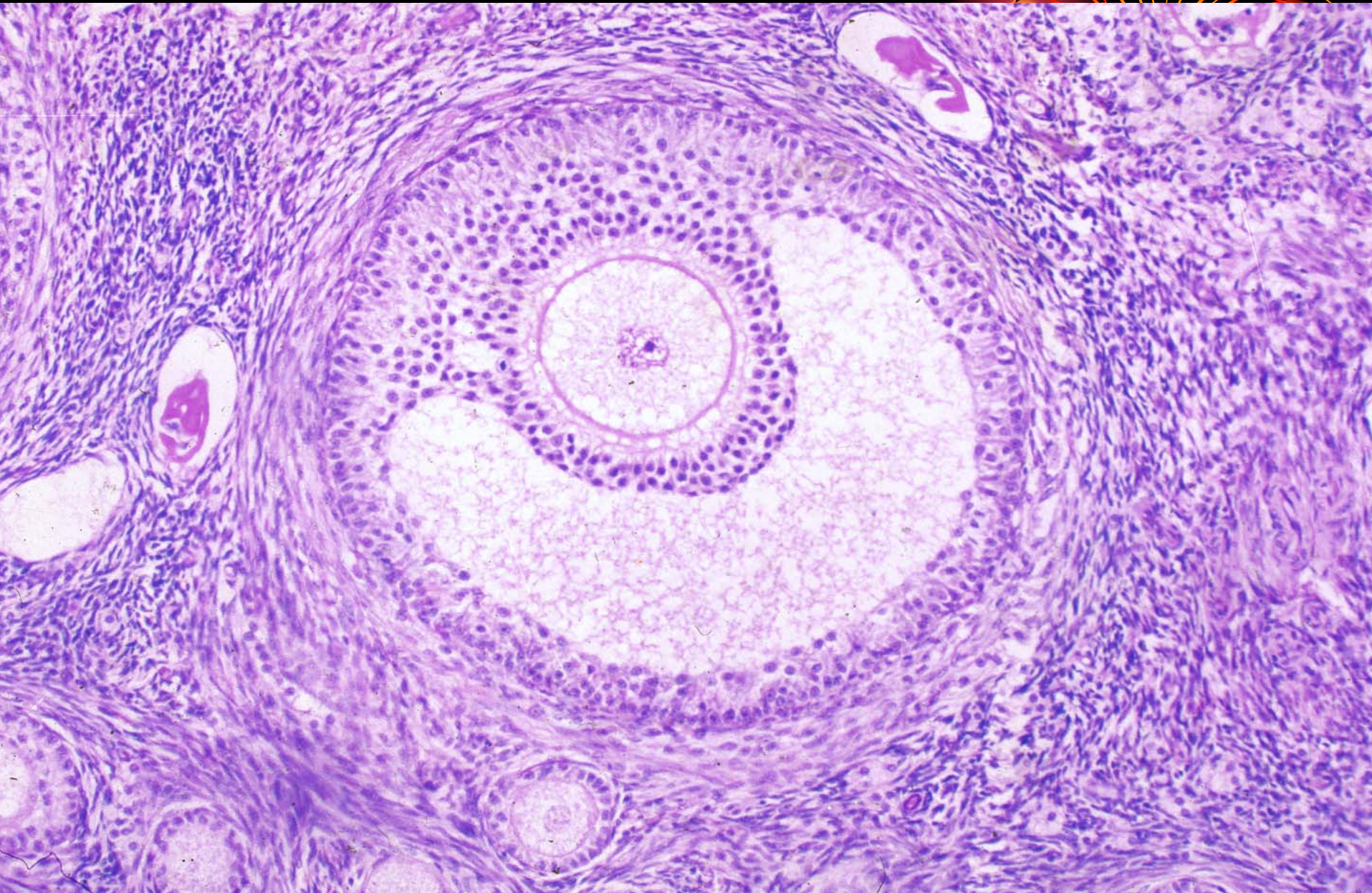


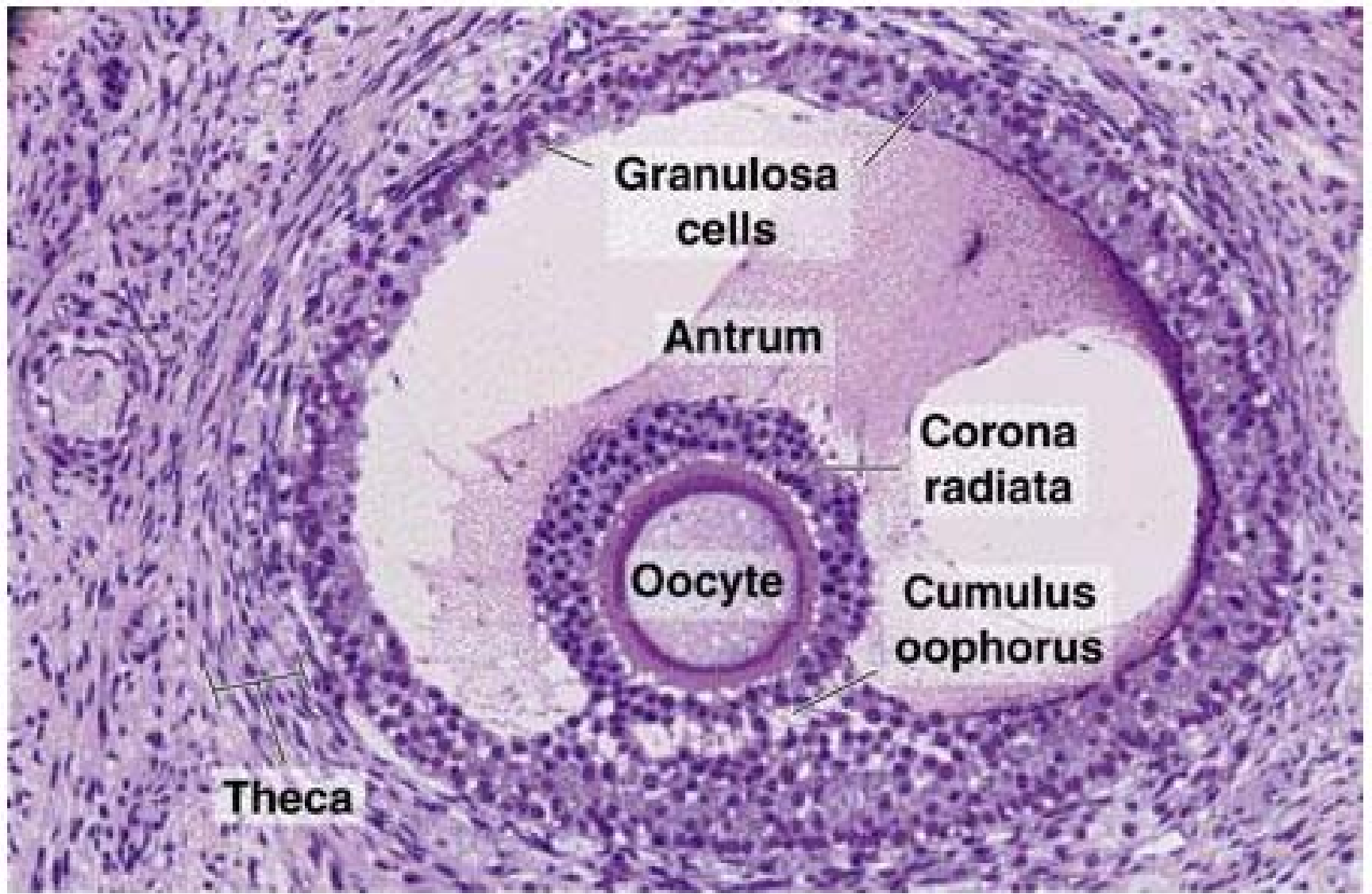
Scanning electron micrograph of an ovary, showing an oocyte surrounded by follicular cells. The structure covering the oocyte is the zona pellucida, which appears as an irregular meshwork. $\times 2950$. (Courtesy of C Barros.)

(2) secondary follicle

Small fluid-filled spaces become visible between the granulosa cells as the follicle reaches a diameter of about 400 μm . These spaces enlarge and fuse to form the follicular antrum, which is the defining feature of the secondary follicle. The oocyte is now located eccentric in the follicle in the cumulus oophorus, where it is surrounded by granulosa cells. The theca folliculi differentiates with the continued growth of the follicle into a theca interna and a theca externa. Vascularization of the theca interna improves, and the cells in this layer start to produce oestrogens. The theca externa retains the characteristics of a highly cellular connective tissue with smooth muscle cells. The oocyte of the secondary follicle reaches a diameter of about 125 μm . The follicle itself reaches a diameter of about 10-15 mm.


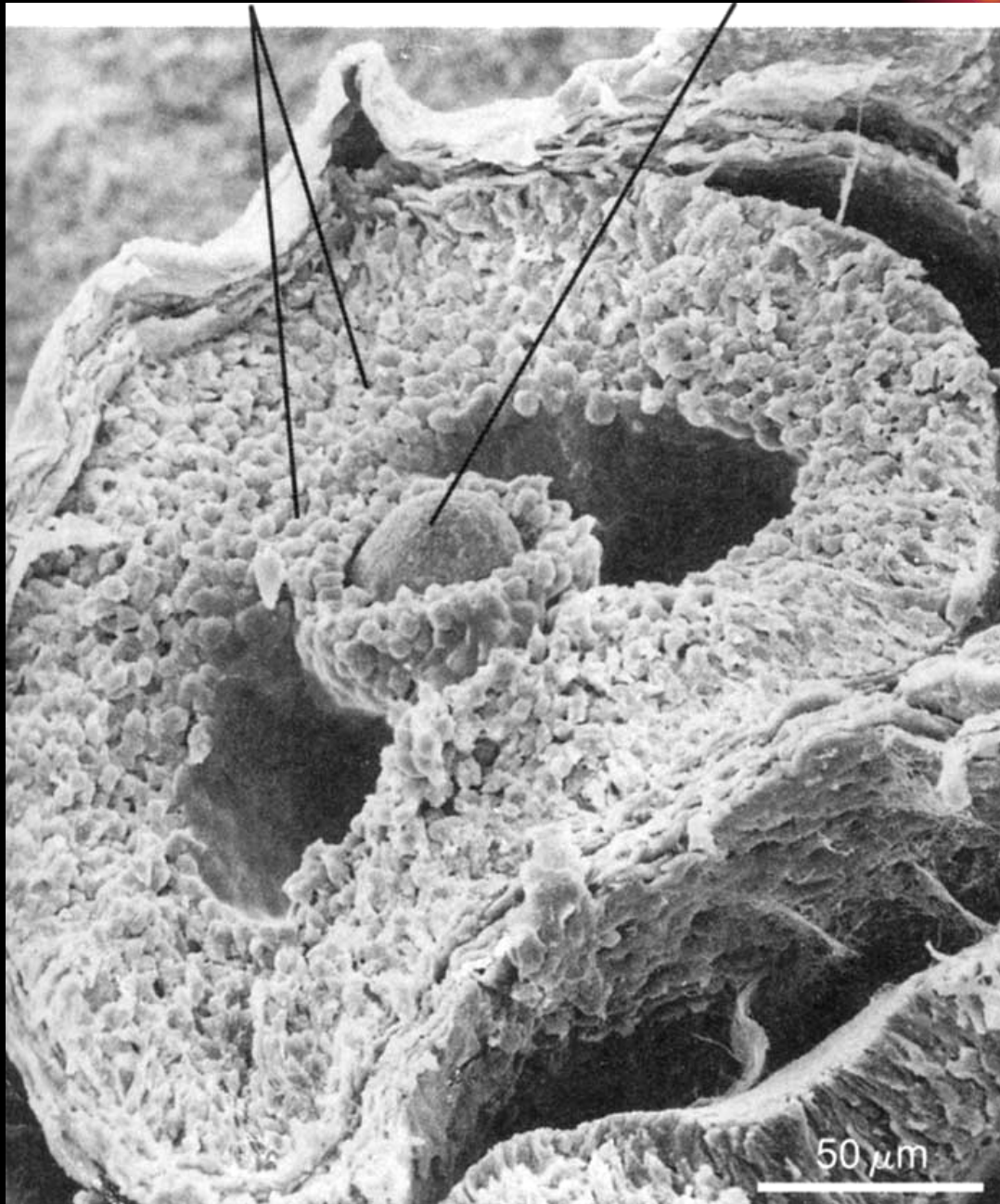


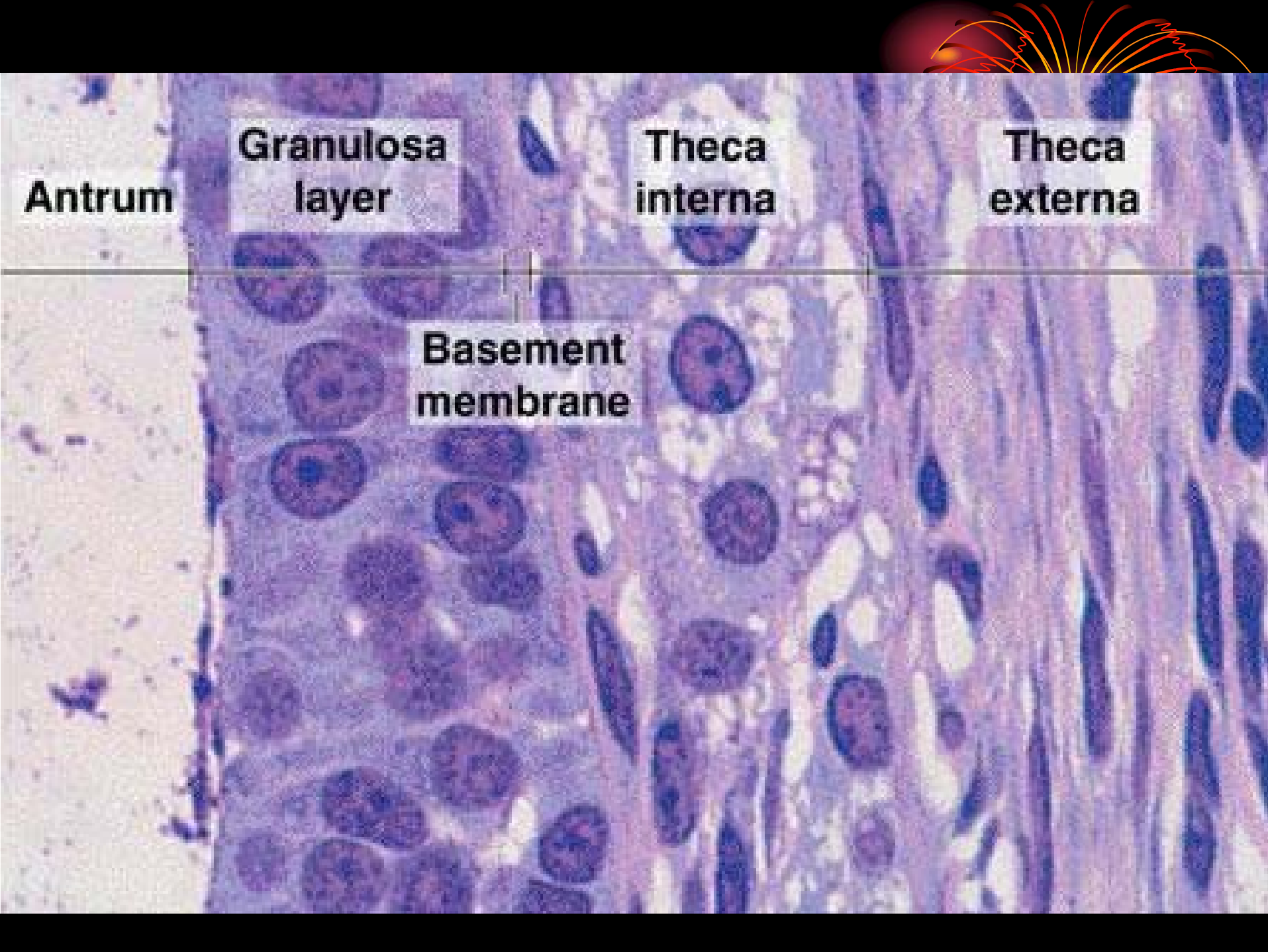




颗粒细胞

初级卵母细胞





Antrum

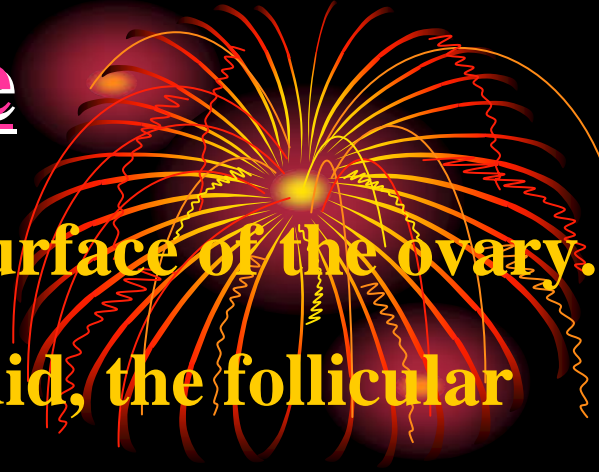**Granulosa
layer**

**Theca
interna**

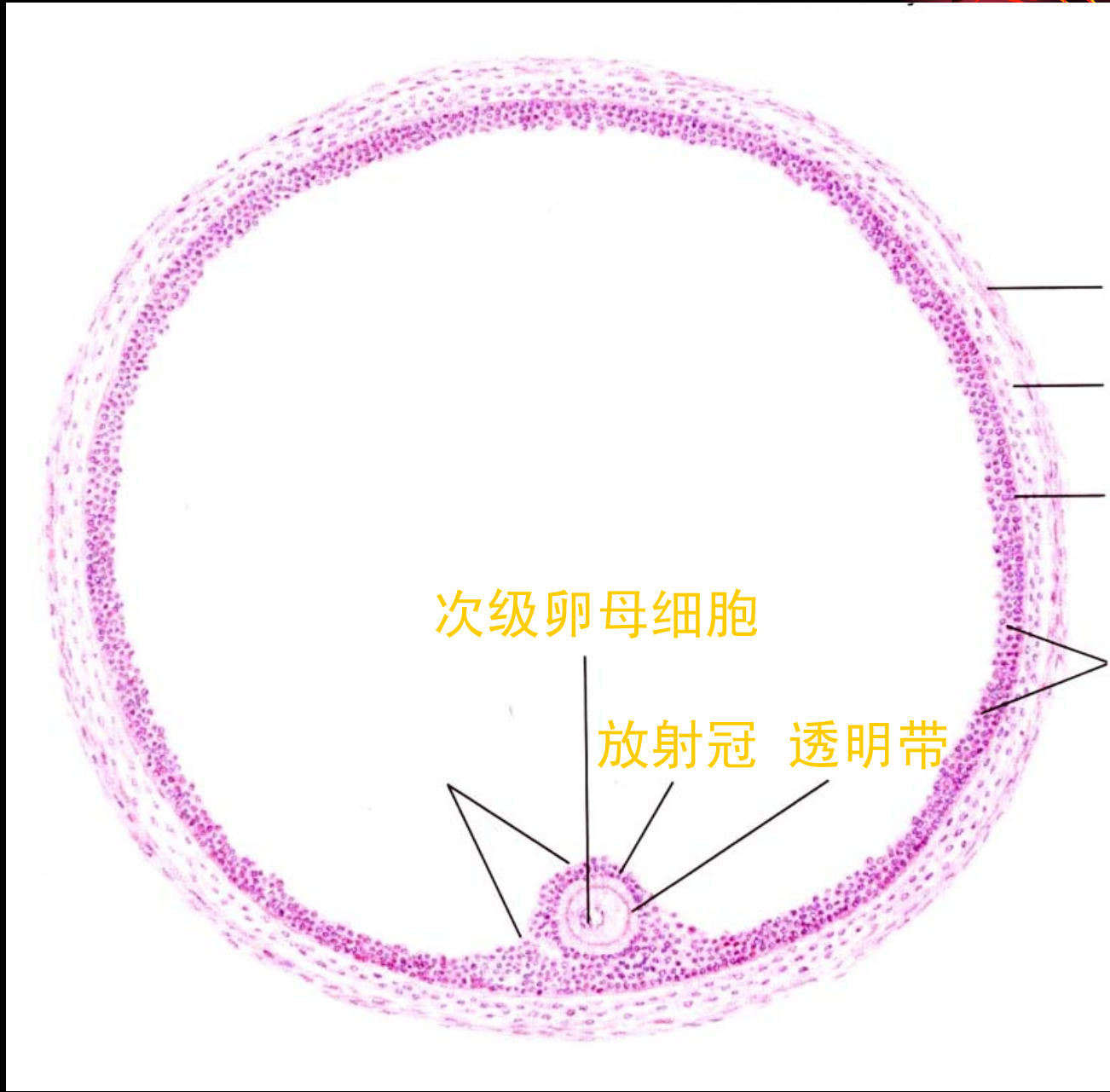
**Theca
externa**

**Basement
membrane**

3. mature follicle




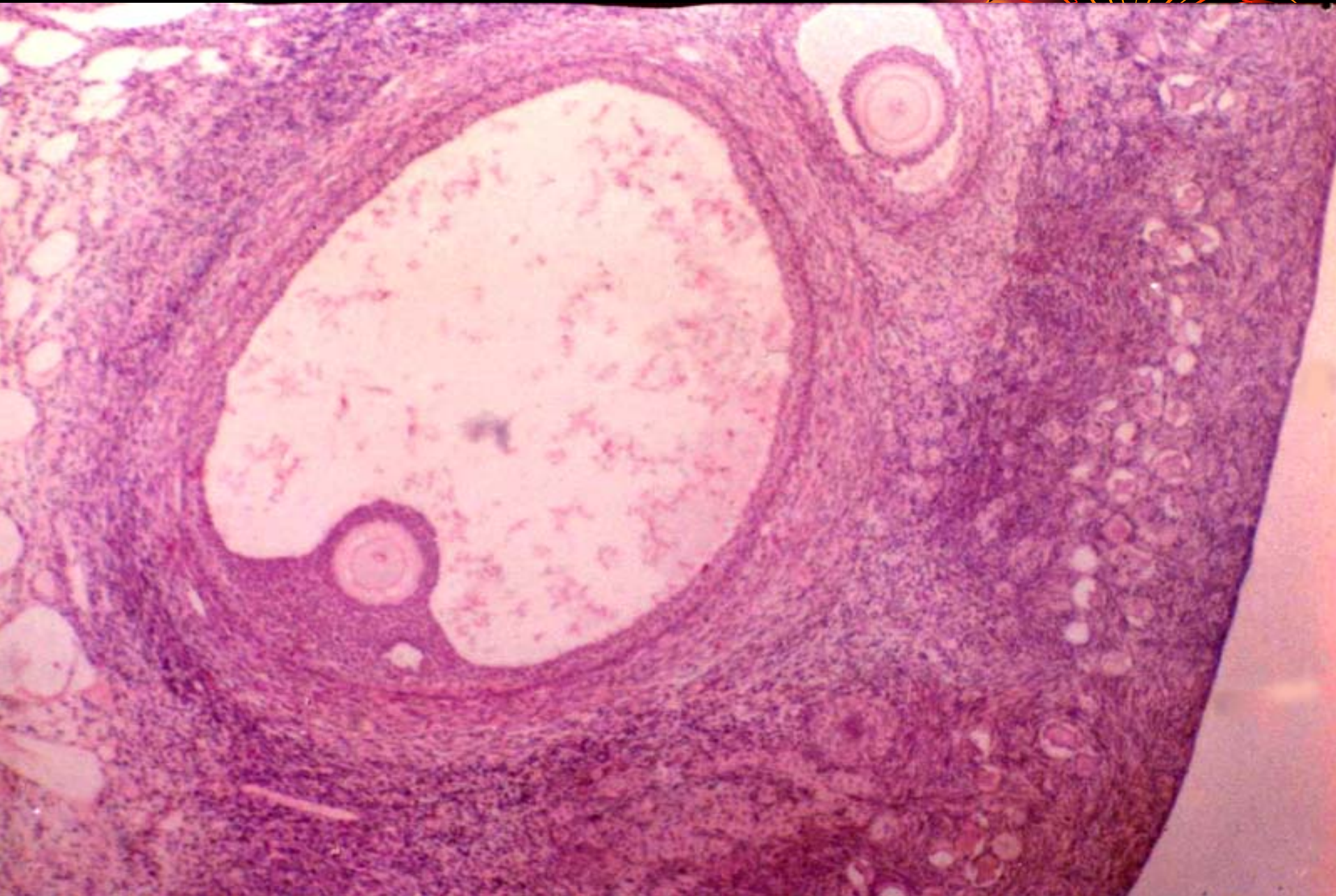
- is so large that it protrudes from the surface of the ovary.
- As a result of the accumulation of liquid, the follicular cavity increases in size.
- Since the granulosa cells of the follicle wall do not multiply in proportion to the growth of the follicle, the granulosa layer becomes thinner.
- These follicles have a very thick theca layer.
- Shortly before ovulation , the first meiotic division is completed and the second meiotic division begins. From then on ,the oocyte is termed a secondary oocyte



次级卵母细胞

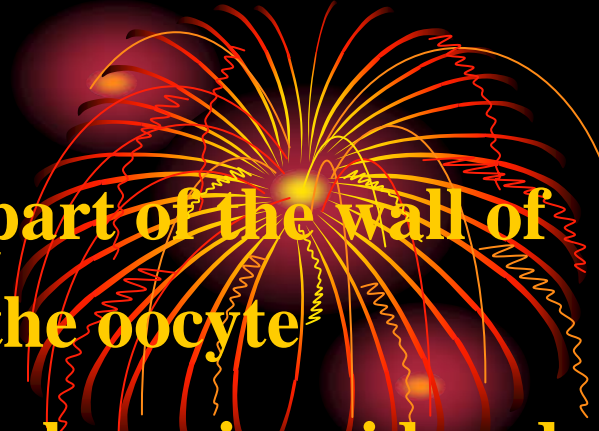放射冠 透明带



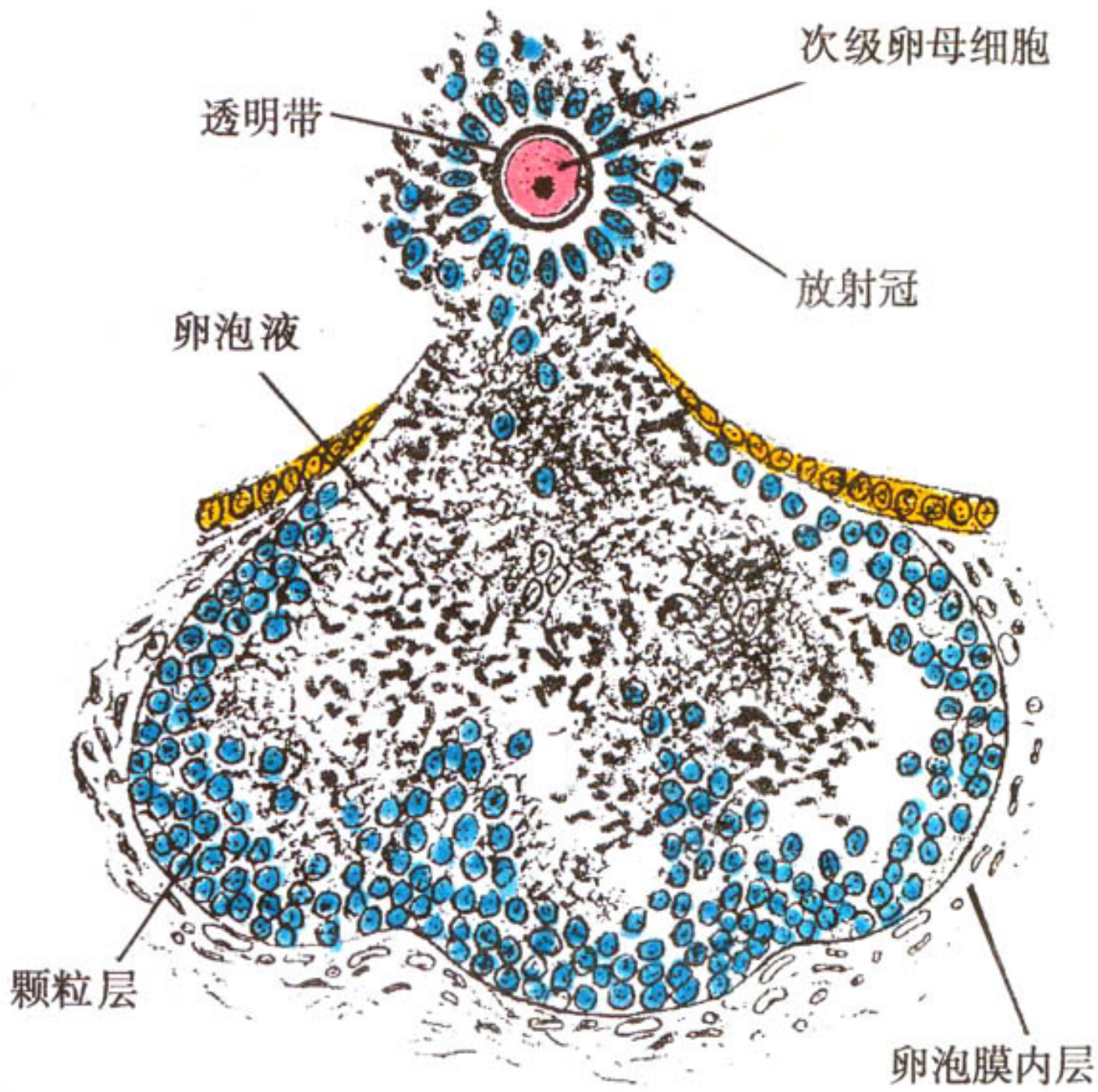


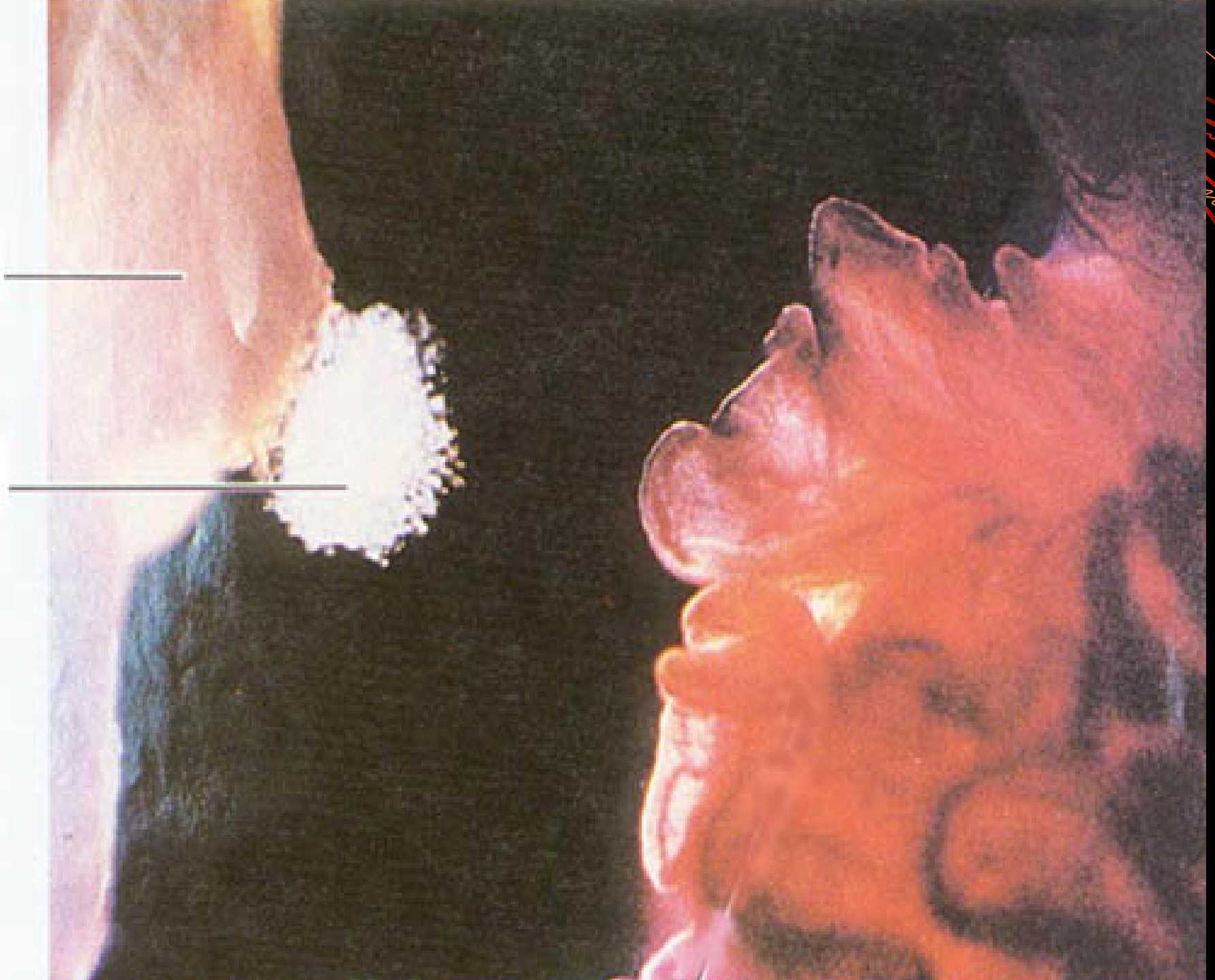


ovulation

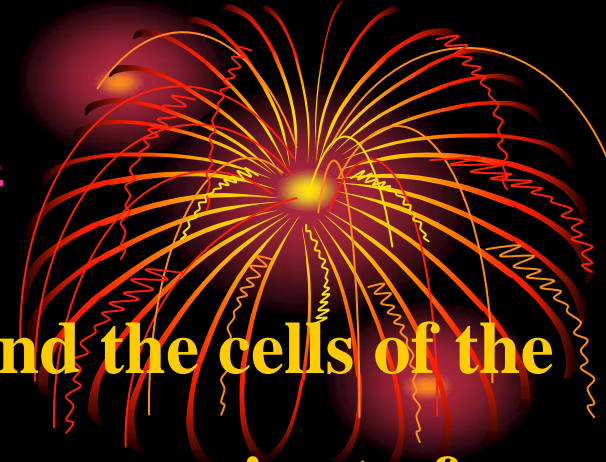- **Ovulation consists of the rupture of part of the wall of the mature follicle and liberation of the oocyte**
- **The granulosa cells produce more hyaluronic acid and become loose. A small area of the wall of the follicle becomes weak. This weakness, combined with an increased pressure of the follicular fluid and possibly the contraction of smooth muscle cells, leads to the rupture of the outer follicular wall and ovulation**
- **the oocyte and the first polar body, enclosed by the zona pellucida, the corona radiata, and some follicular fluid, leave the ovary.**



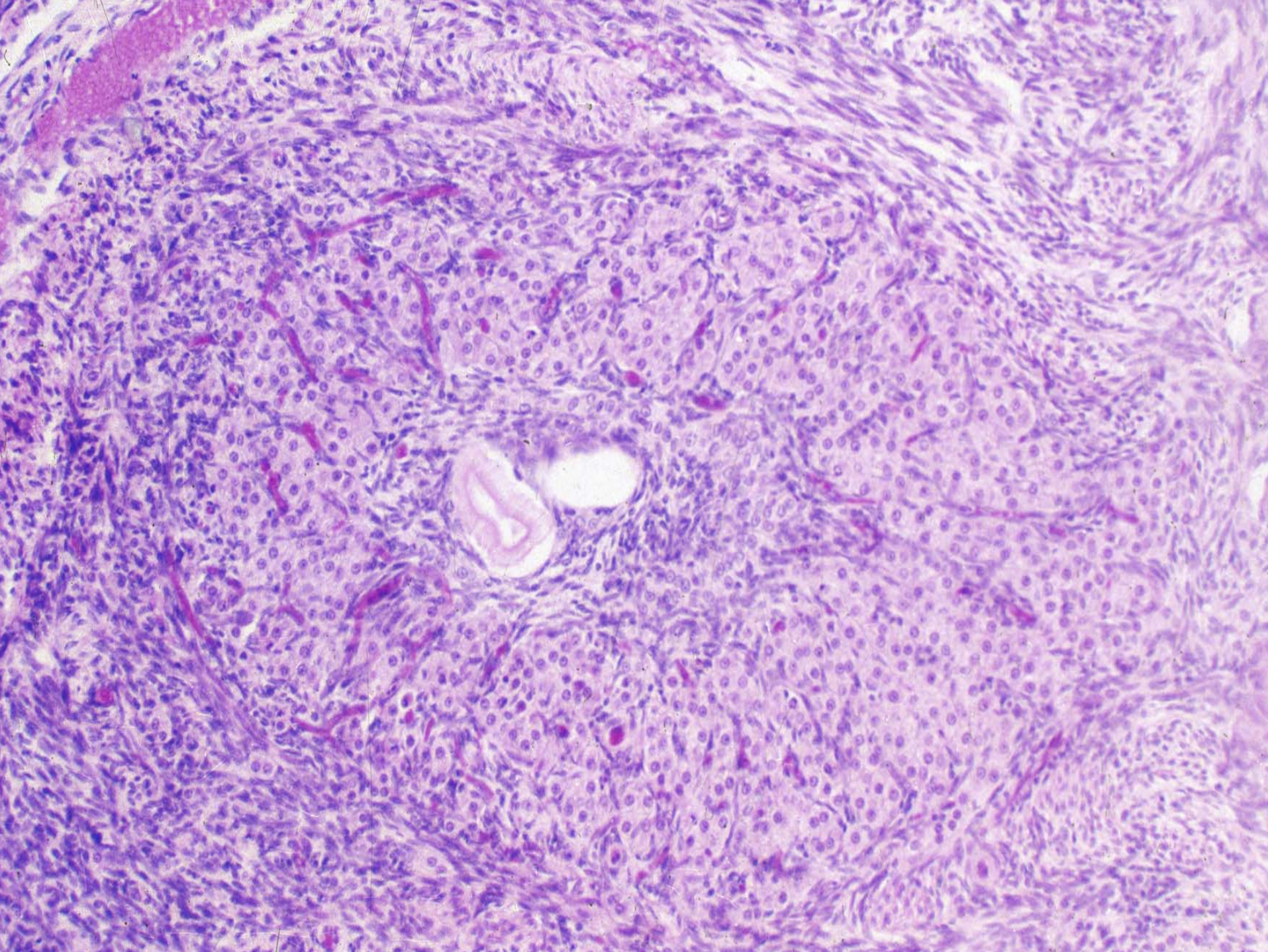





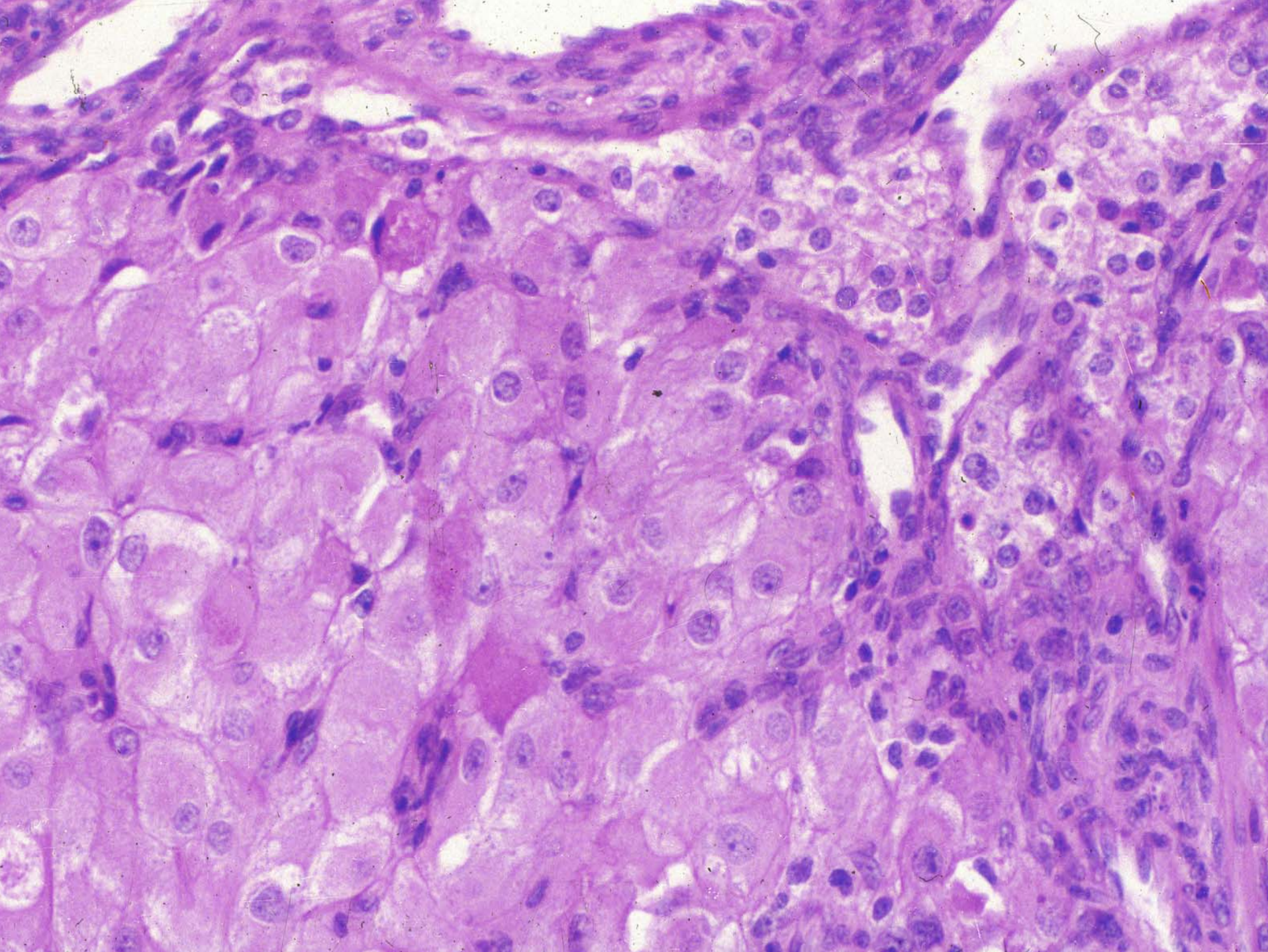
Corpus Luteum



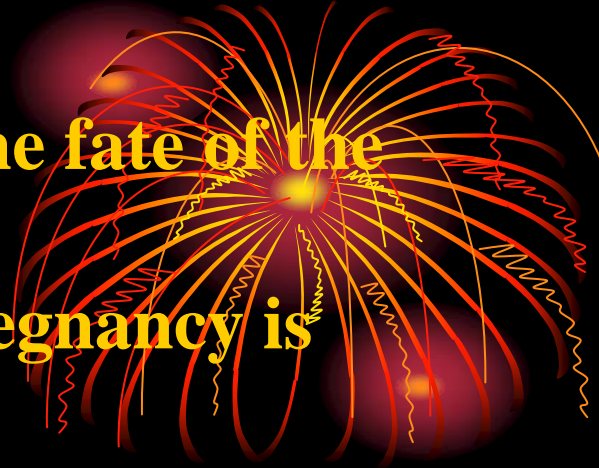- After ovulation, the granulosa cells and the cells of the theca interna of the ovulated follicle reorganize to form a temporary endocrine gland called the corpus luteum
- the granulosa cells increase greatly in size . They make up about 80% of the parenchyma of the corpus luteum and are then called granulosa lutein cells, with the characteristics of steroid-secreting cells.



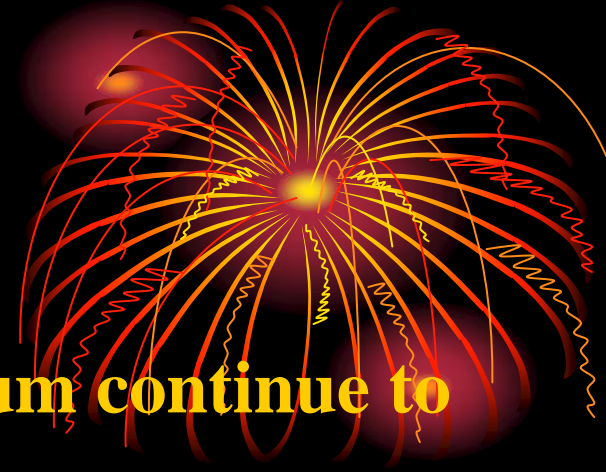- 
- **Cells of the theca interna also contribute to the formation of the corpus luteum by giving rise to theca lutein cells. These cells are similar in structure to granulosa lutein cells but are smaller and stain more intensely. They are located in the folds of the wall of the corpus luteum.**
 - **the cells of the corpus luteum change their sets of enzymes and begin secreting progesterone and estrogens.**



- **the corpus luteum of menstruation :The fate of the corpus luteum depends on whether pregnancy is established. Following the stimulus by LH, the corpus luteum is programmed to secrete for 10–12 days. Then the cells of the corpus luteum degenerate by apoptosis. The corpus luteum that lasts only part of a menstrual cycle is called the corpus luteum of menstruation.**

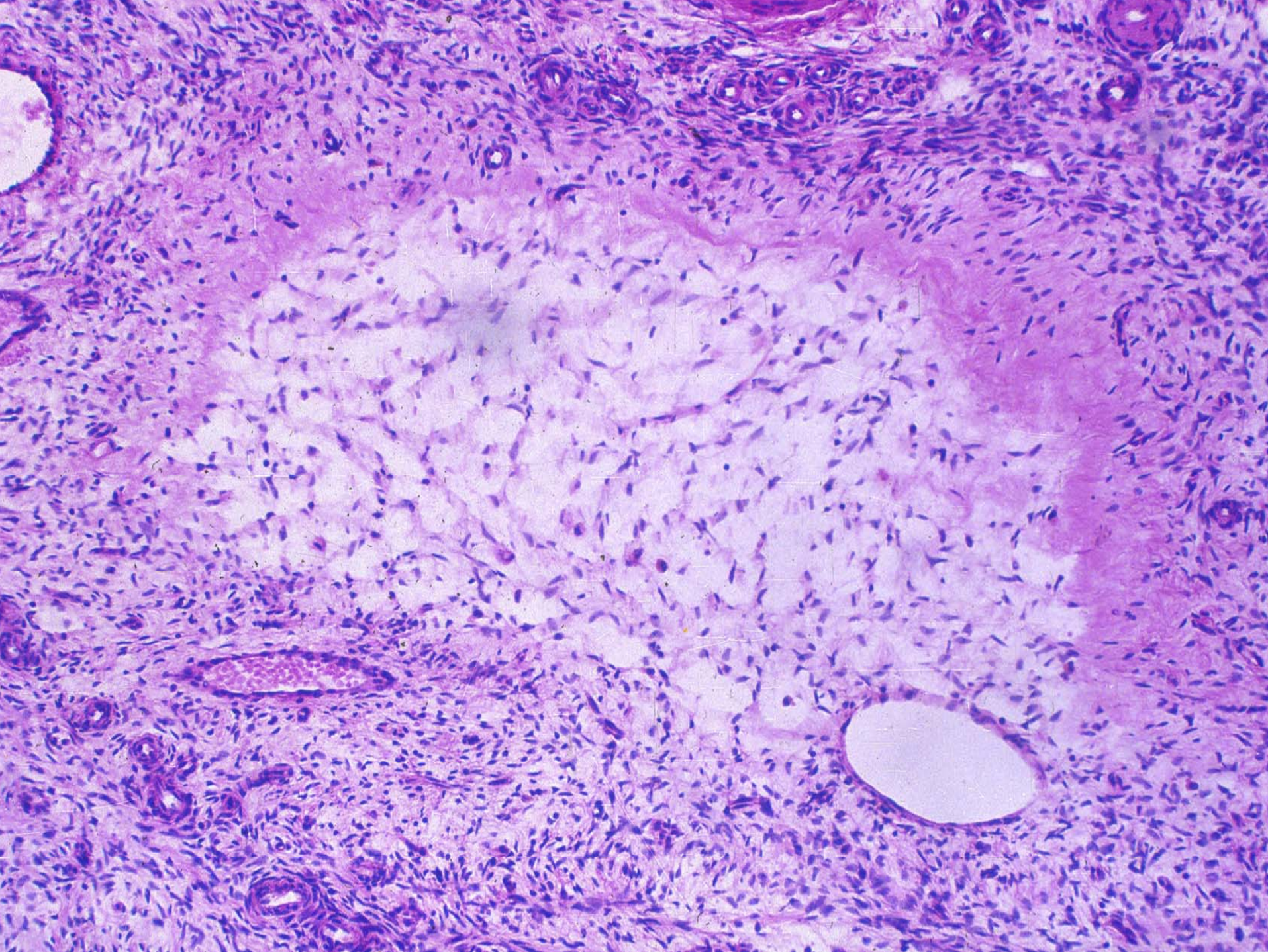


- **corpus luteum of pregnancy**

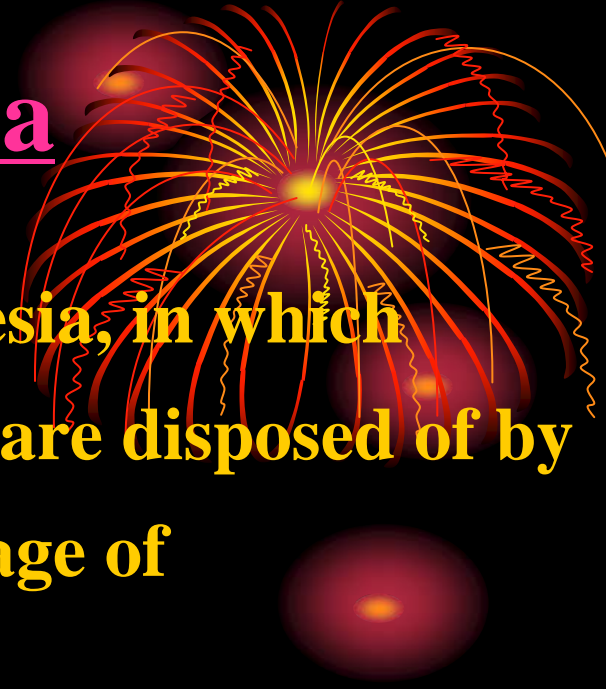

If pregnancy occurs, the corpus luteum continue to grow, and to secrete progesterone . It persists for 4–5 months and then degenerates

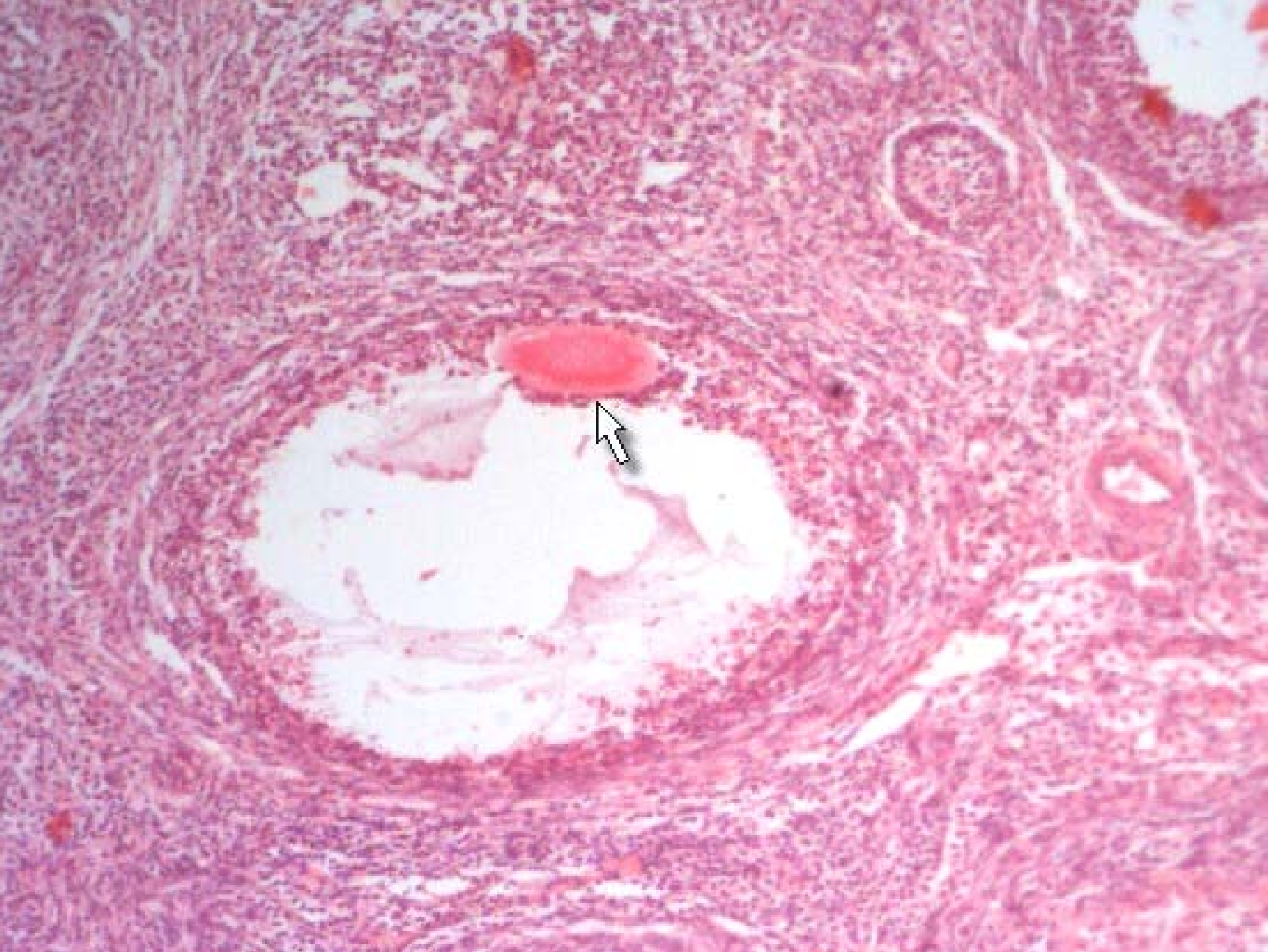
- **Neighboring fibroblasts invade the area and produce a scar of dense connective tissue called corpus albicans**

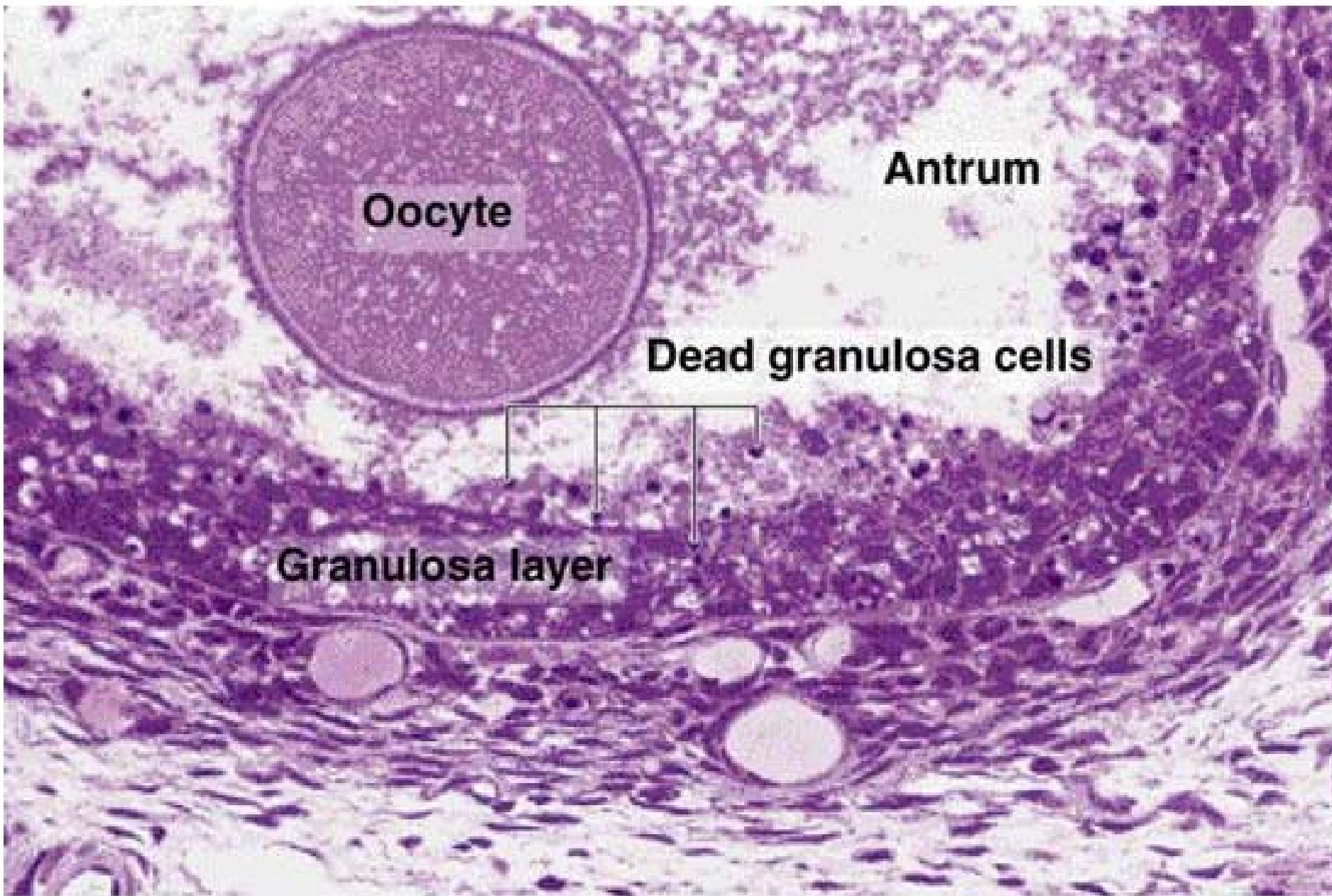


Follicular Atresia



- **Most ovarian follicles undergo atresia, in which follicular cells and oocytes die and are disposed of by phagocytic cells. Follicles at any stage of development may undergo atresia.**
- **This process is characterized by cessation of mitosis in the granulosa cells, detachment of granulosa cells from the basal lamina, and death of the oocyte. After cell death, macrophages invade the follicle to phagocytose the debris.**





Oocyte

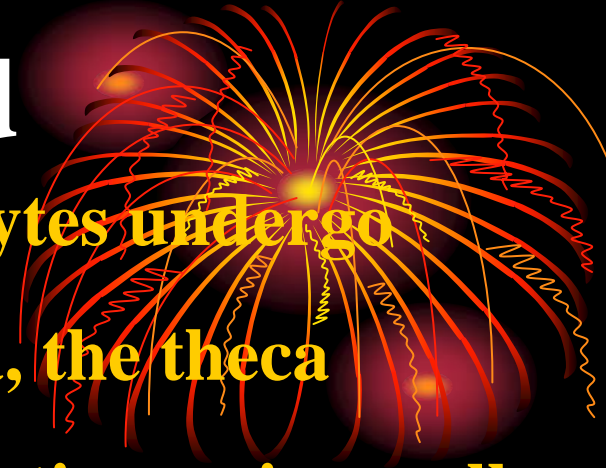Antrum

Dead granulosa cells

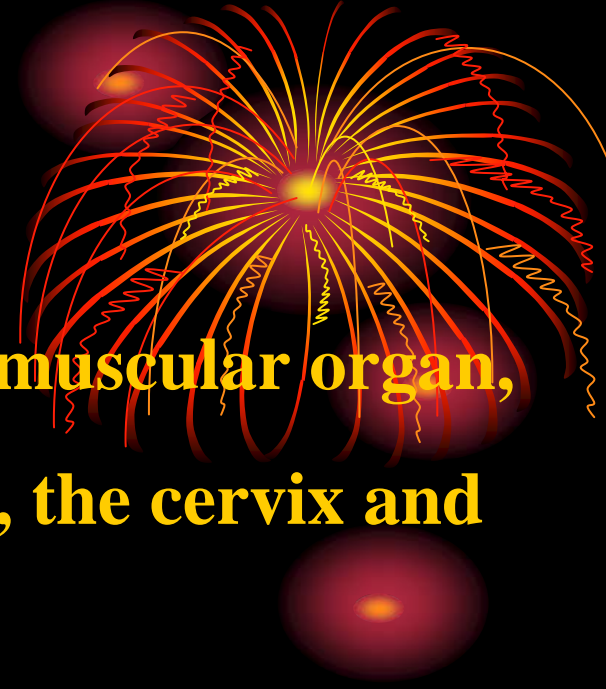Granulosa layer

Interstitial gland

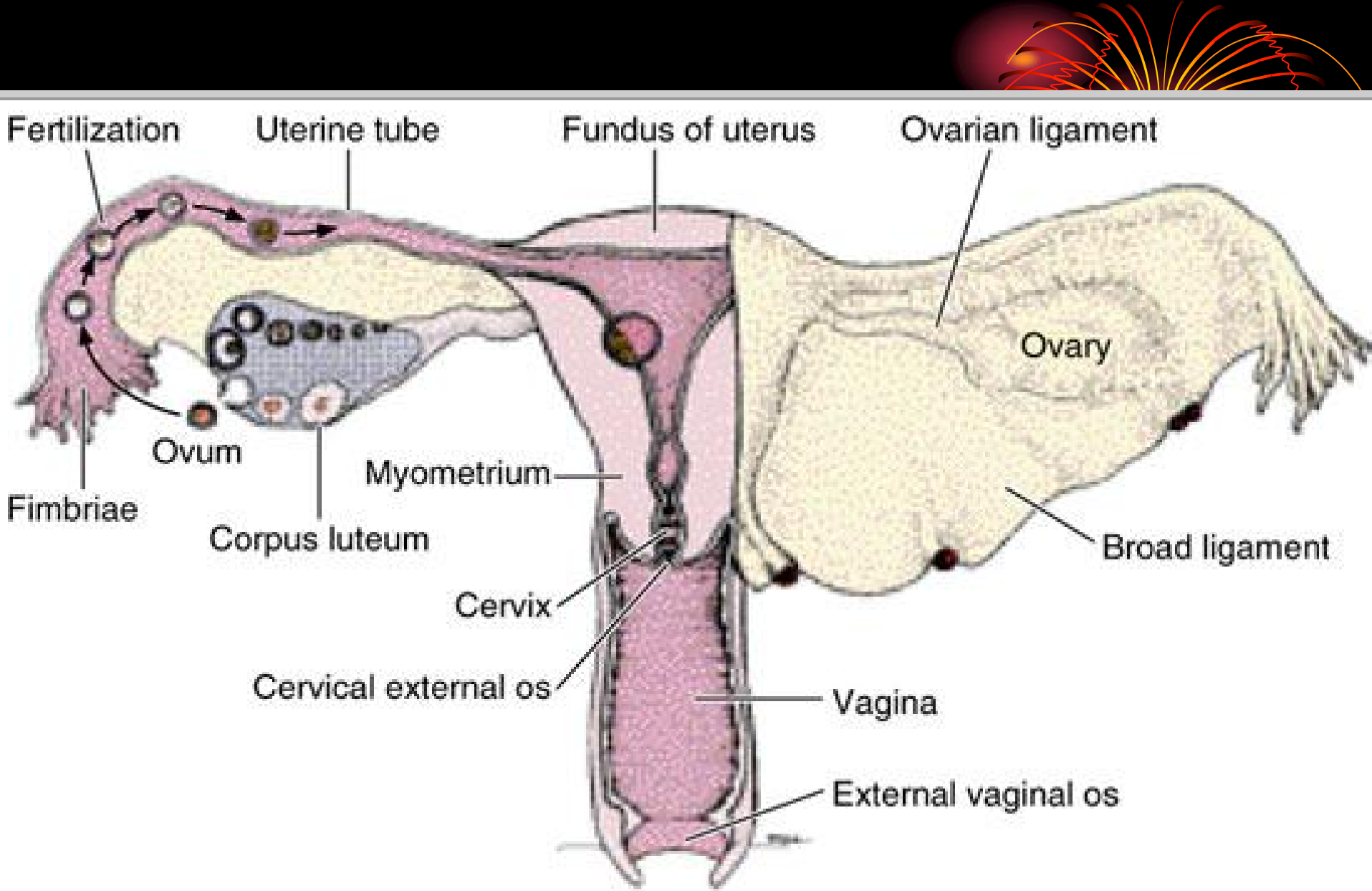
- **Although granulosa cells and the oocytes undergo degeneration during follicular atresia, the theca interna cells frequently persist in isolation or in small groups throughout the cortical stroma and are called interstitial gland.**
- **The gland is well-developed in some mammals , particularly rodents. however, in the adult human ovary, the interstitial cells are either absent or very poorly represented**



II. uterus



- **The uterus is a thick –walled hollow muscular organ, which is consisted of a body (corpus), the cervix and the fundus**
- **The wall is formed of 3 layers.**
 - either an outer serosa or adventitia .**
 - the myometrium, a thick tunic of smooth muscle**
 - the endometrium, or mucosa of the uterus.**



Internal organs of the female reproductive system.

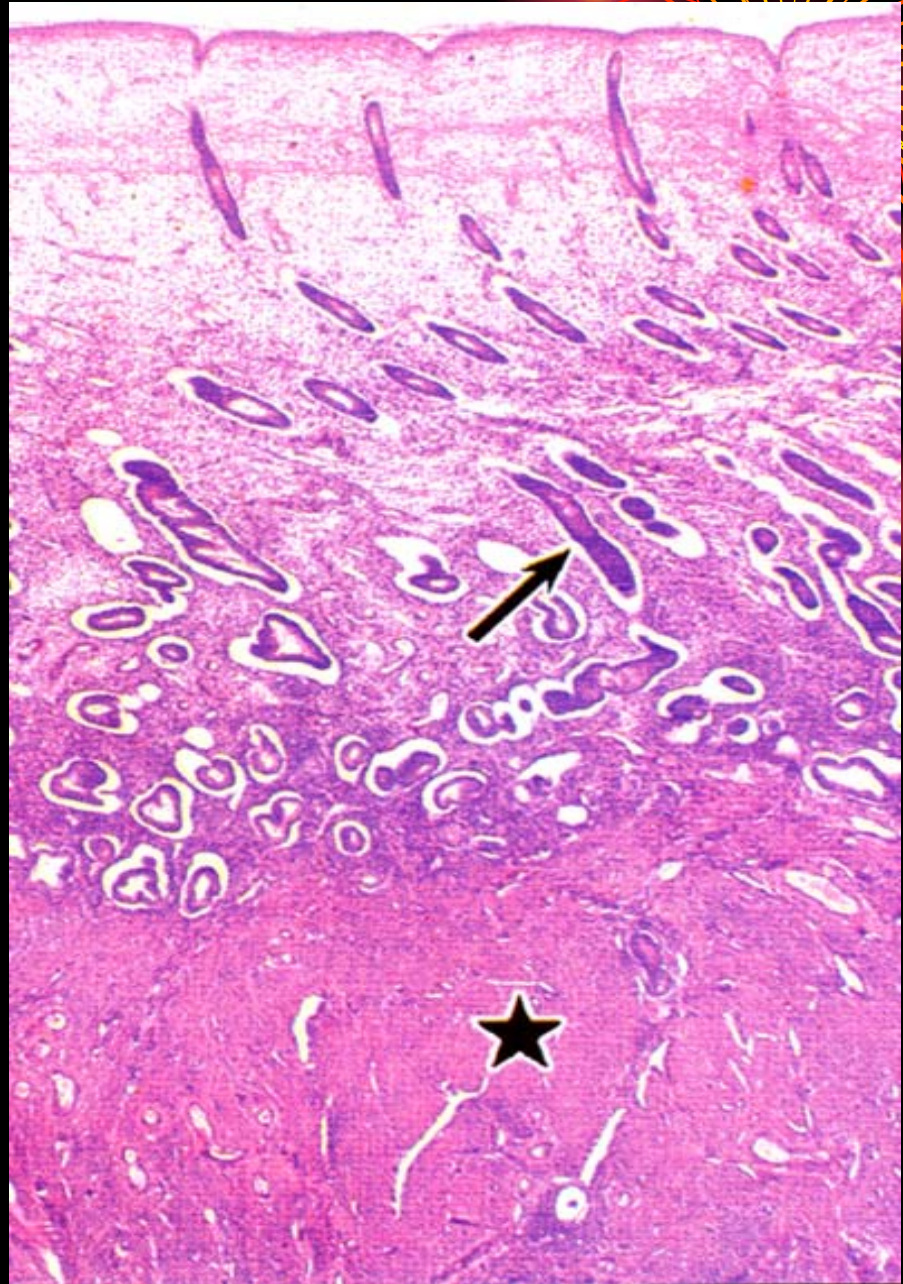


— 上皮

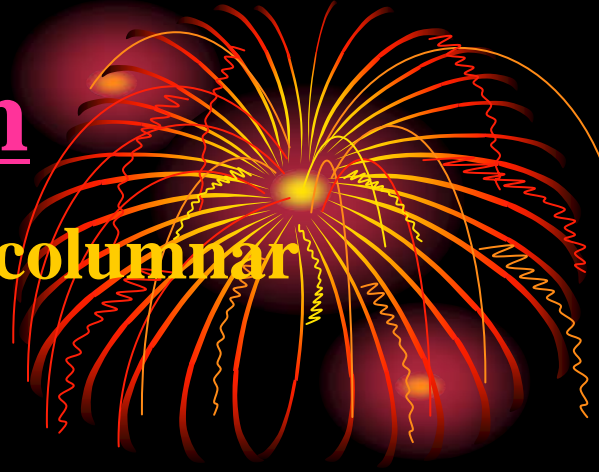— 固有层

肌层


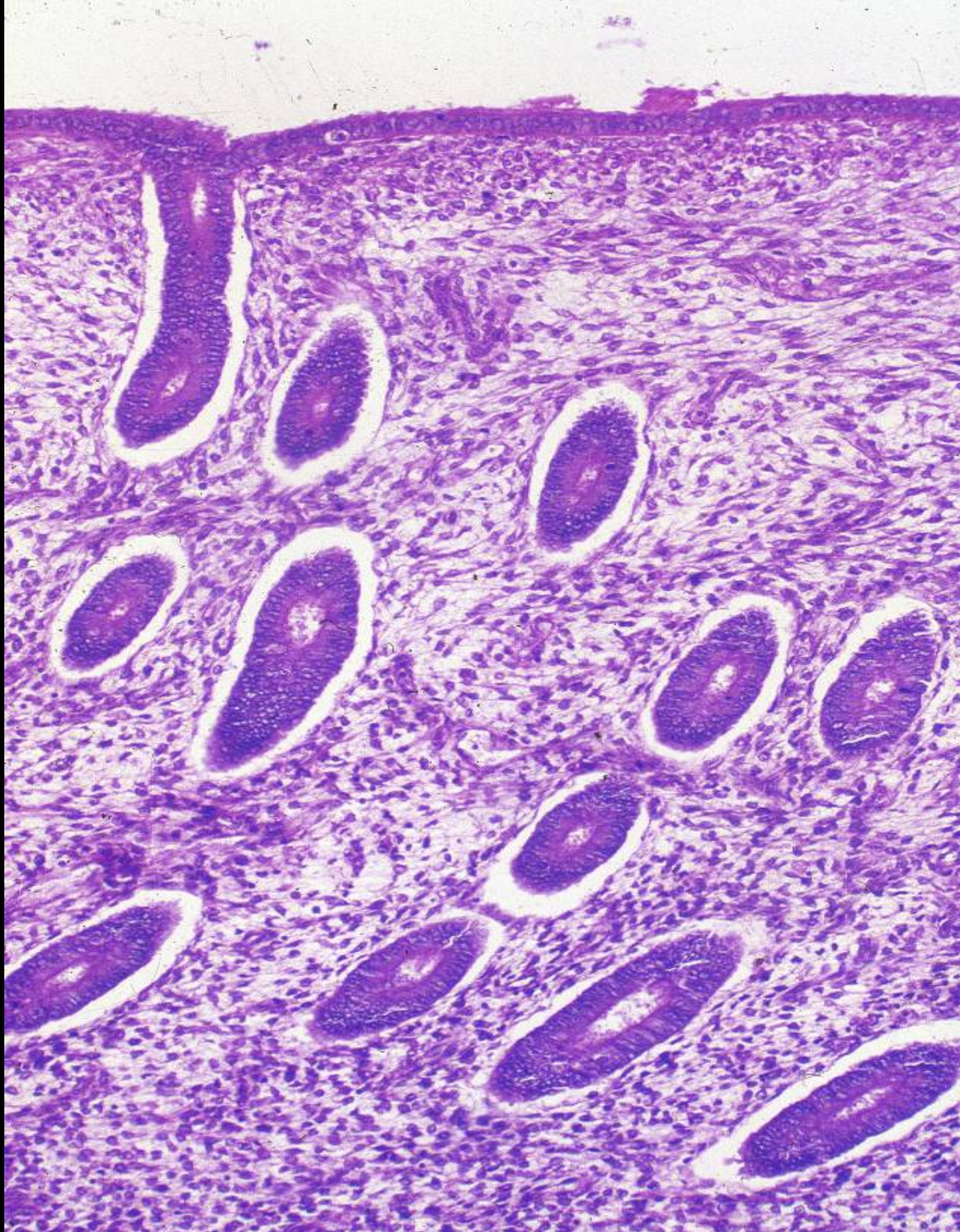
— 浆膜

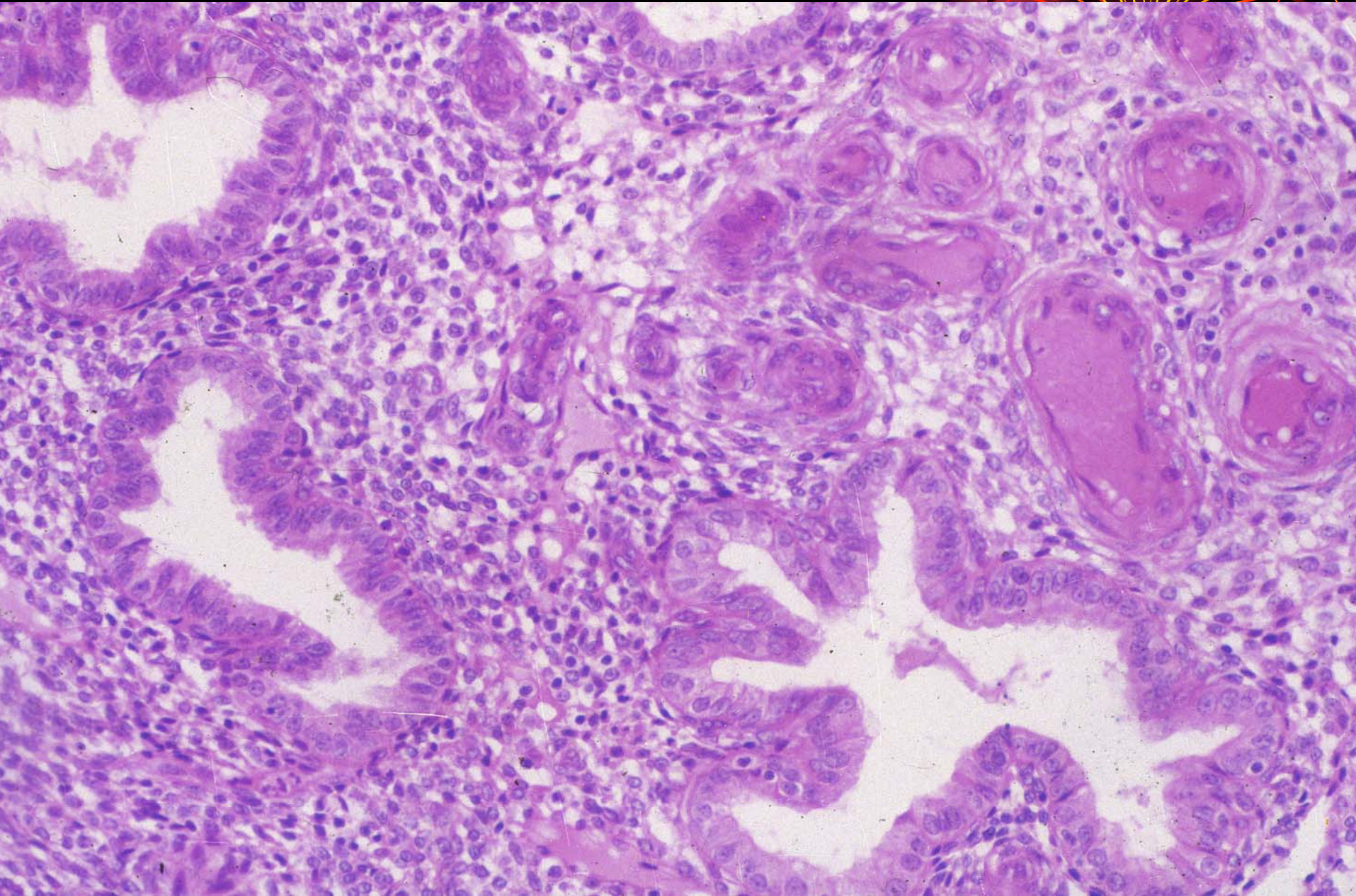


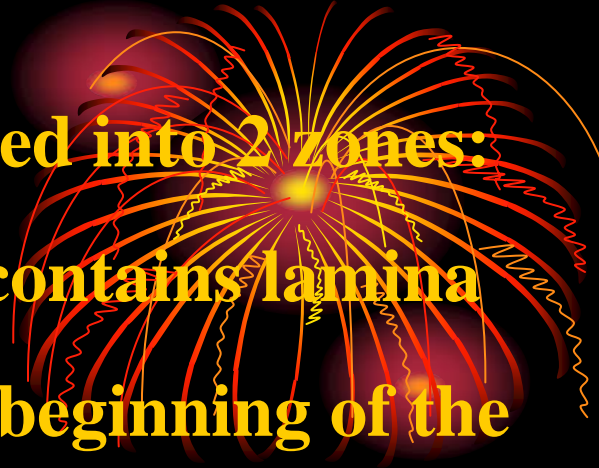Endometrium



- **The endometrium consists of a simple columnar epithelium and a lamina propria**
- **the epithelium is a mixture of ciliated and secretory simple columnar cells.**
- **The lamina propria: containing simple tubular glands.**
The epithelium of the uterine glands is similar to the superficial epithelium, but ciliated cells are rare. The connective tissue of the lamina propria is rich in fibroblasts and contains abundant ground substance and the blood vessels



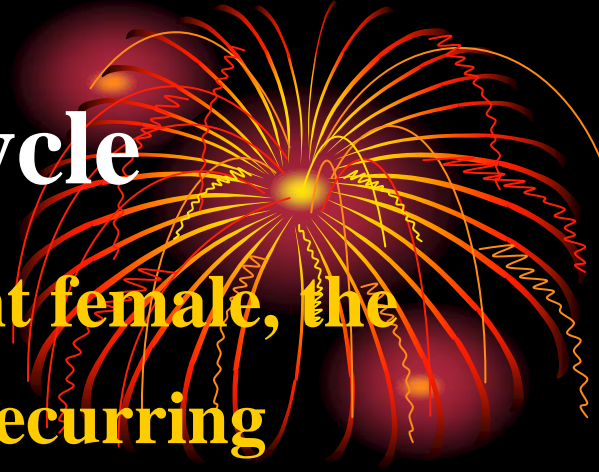



- **The endometrial layer can be subdivided into 2 zones:**
 - (1) **The basalis :** is the deepest one, it contains lamina propria , straight arteries and the beginning of the uterine glands.
 - (2) **The functionalis:** contains the remainder of the lamina propria , spiral arteries and of the glands, as well as the surface epithelium.
- **While the functionalis undergoes profound changes during the menstrual cycles, the basalis remains mostly unchanged.**

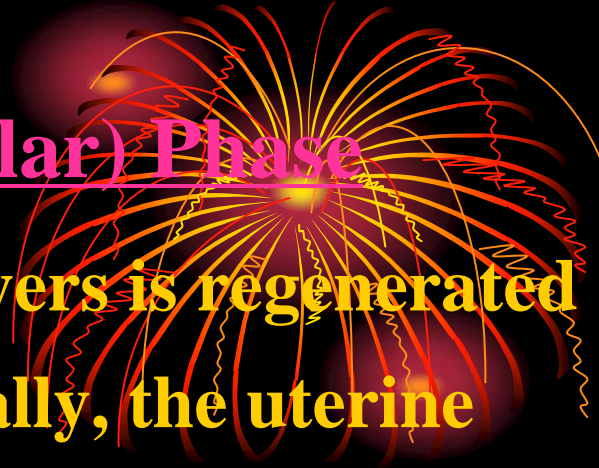The Menstrual Cycle



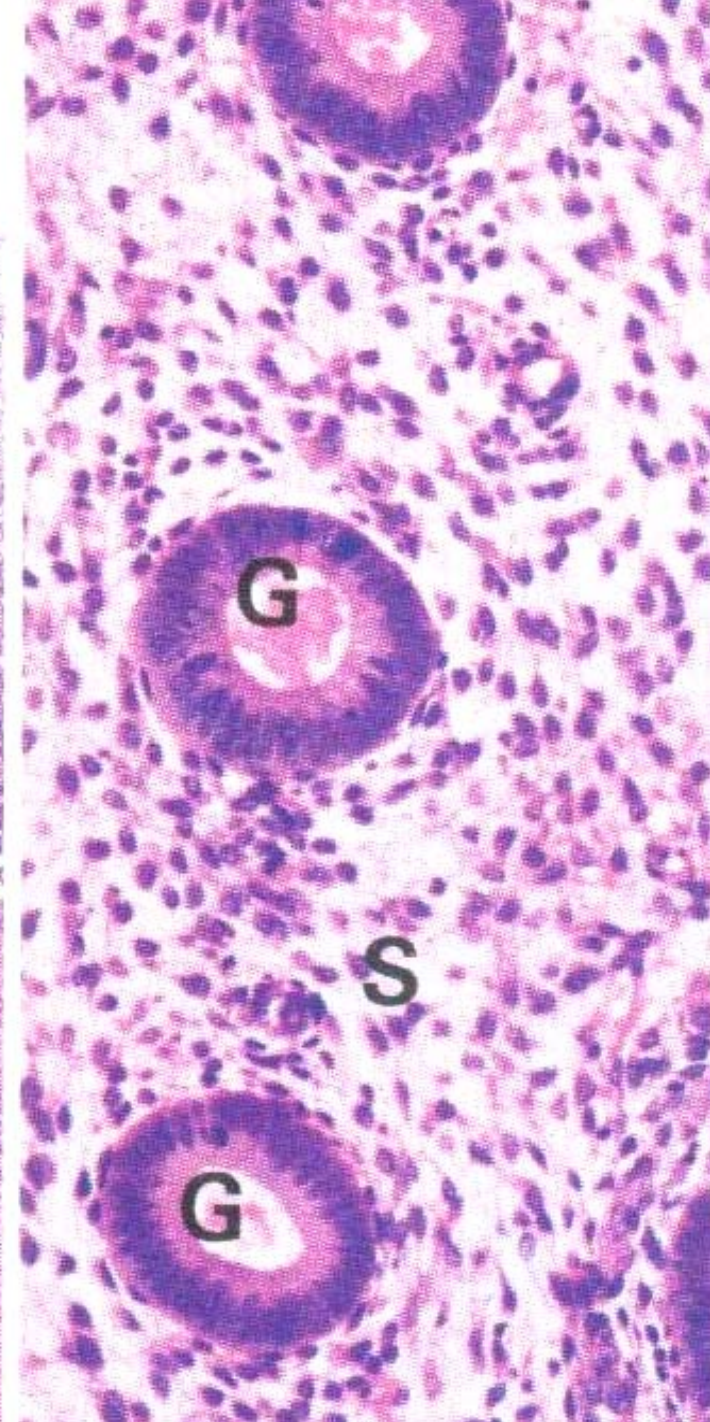
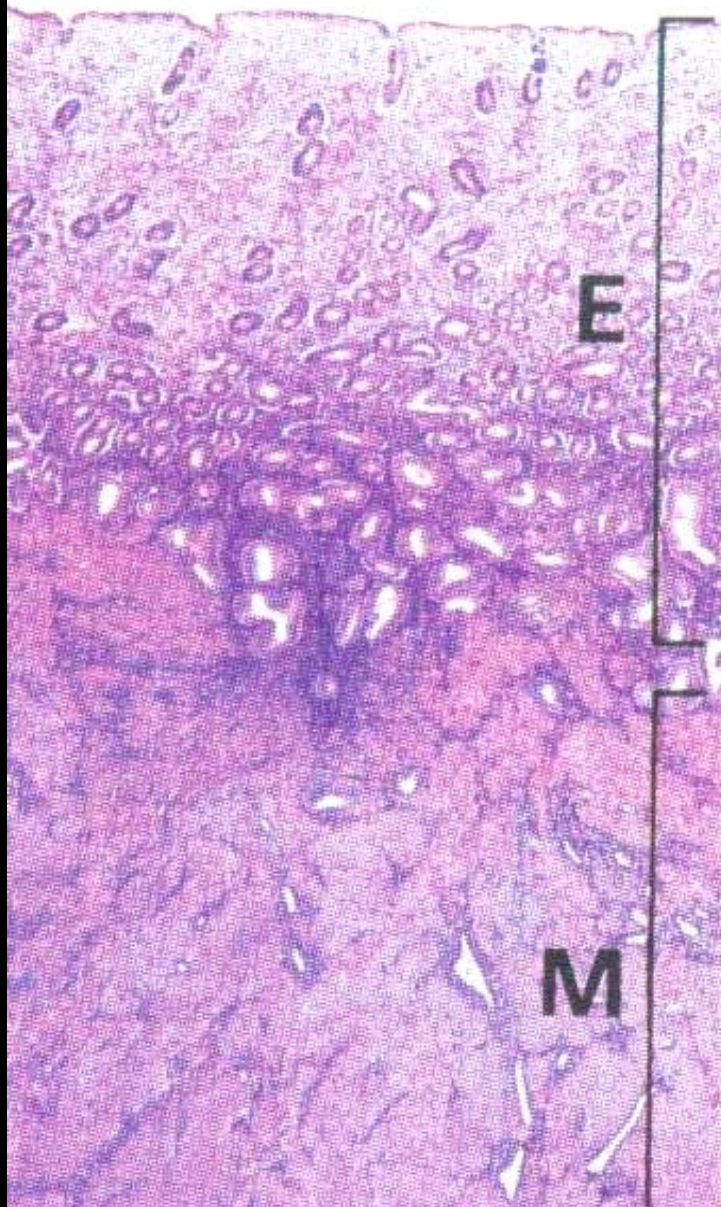
- **In the sexually-mature, non –pregnant female, the genital organs undergo periodically-recurring changes, which are caused by hormones . Such cyclic changes of the hormonal status and of the genitals are termed the menstrual cycle**
- **Cyclic histological changes are most marked in the endometrium of the corpus, where three typical phases can be distinguished : the menstrual phase, the proliferative phase, and the secretory phase.**


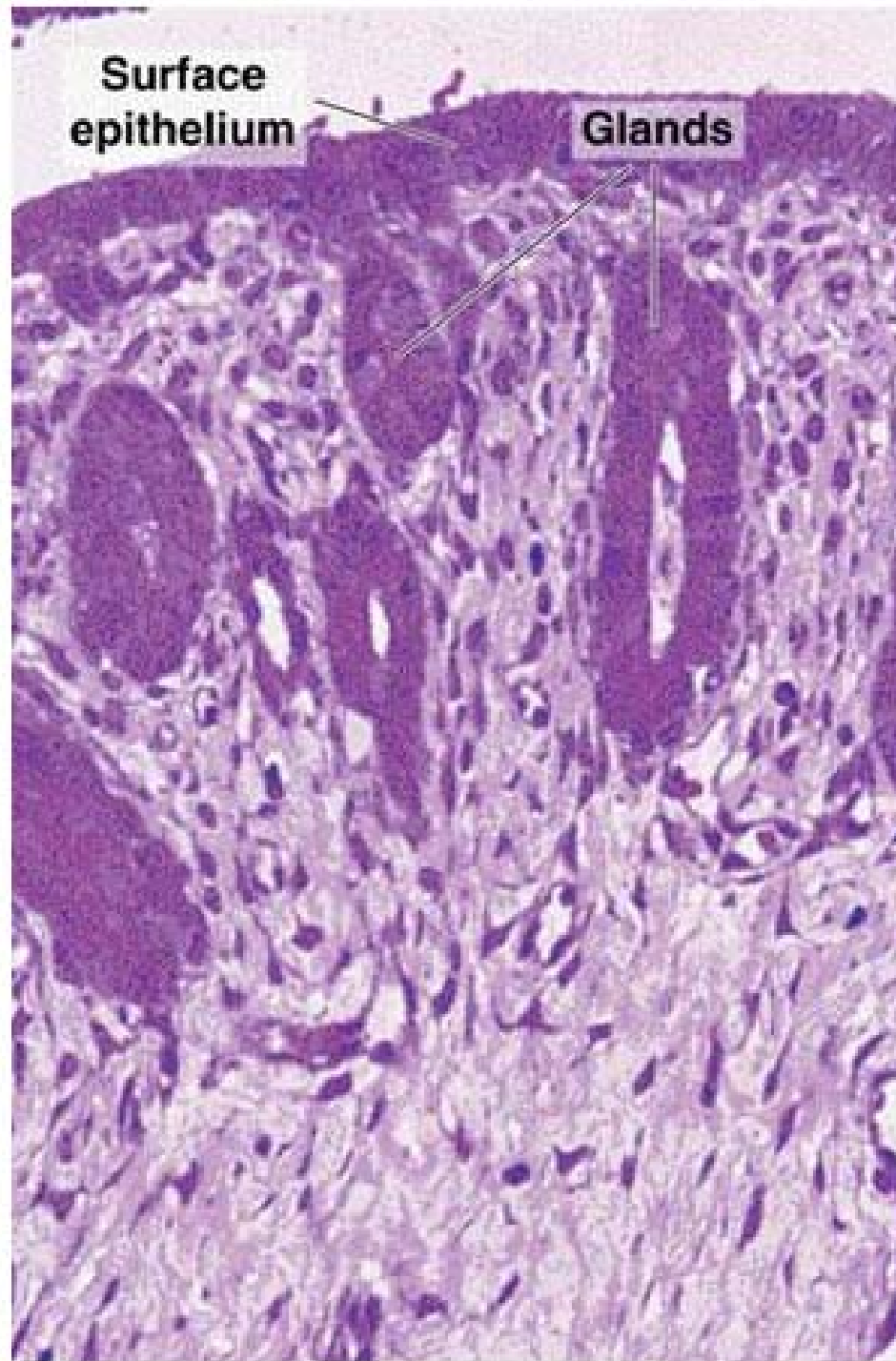

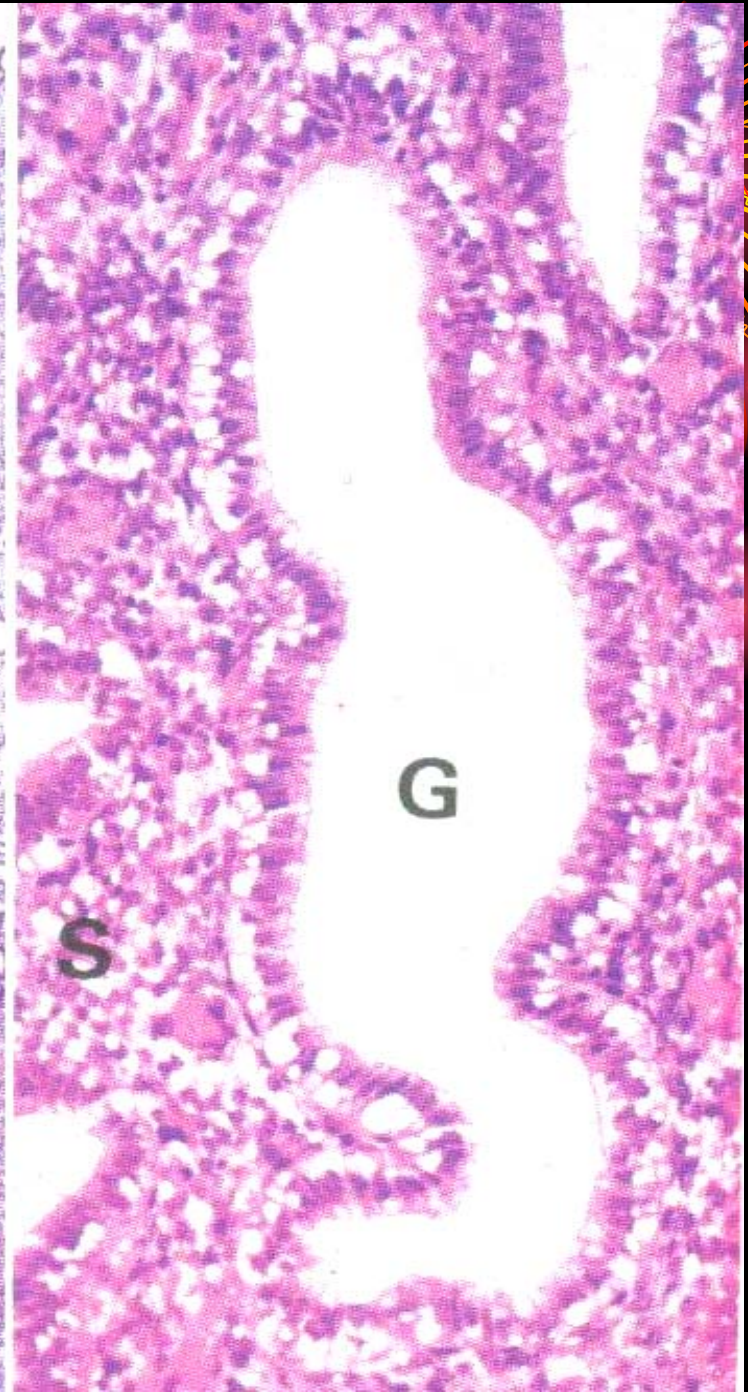

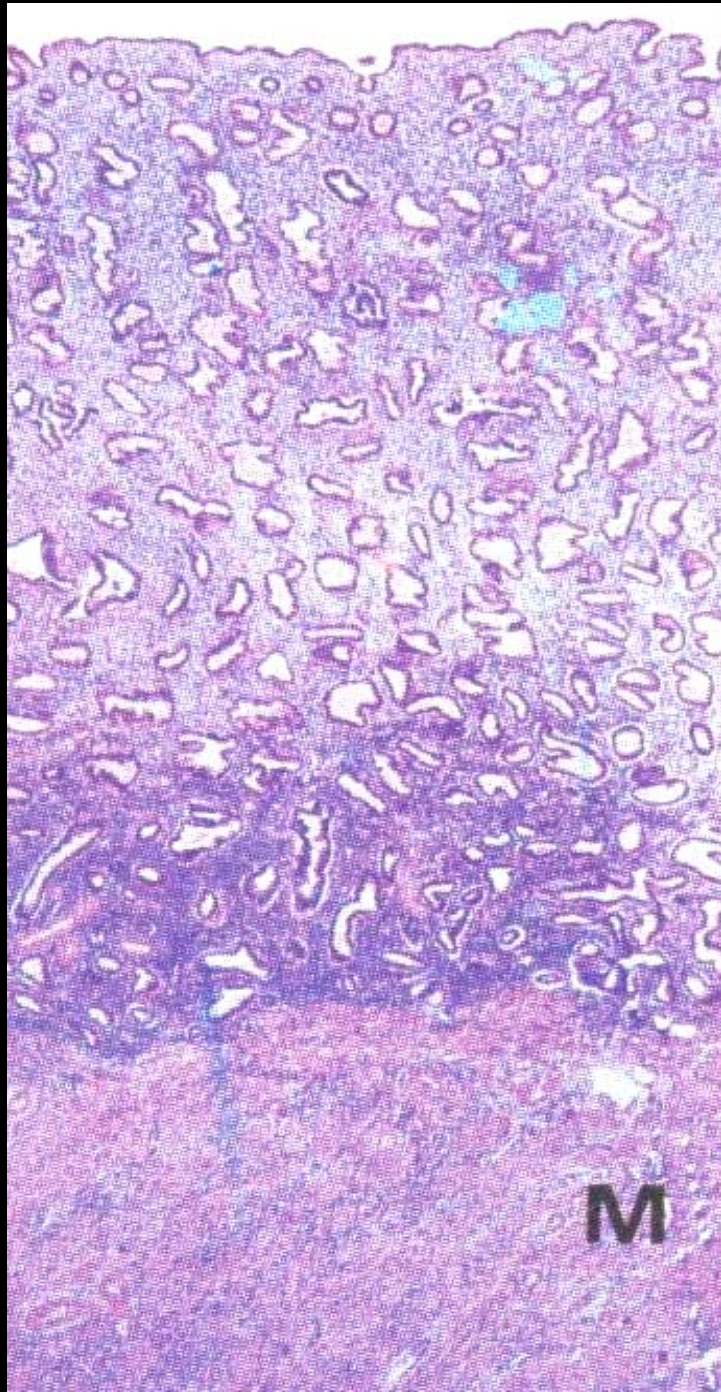
1. The Proliferative (Follicular) Phase

- **After menstruation, the functional layers is regenerated from the cells of the basal layer. Initially, the uterine glands are tubular, but towards the end of the proliferative phase, they become coiled and their cells start to store glycogen. the helical arteries also begin to sprout into the growing functional layer.**
- **during the proliferative phase, the endometrium increases from 1mm(or less) in thickness to 2mm or even more.**



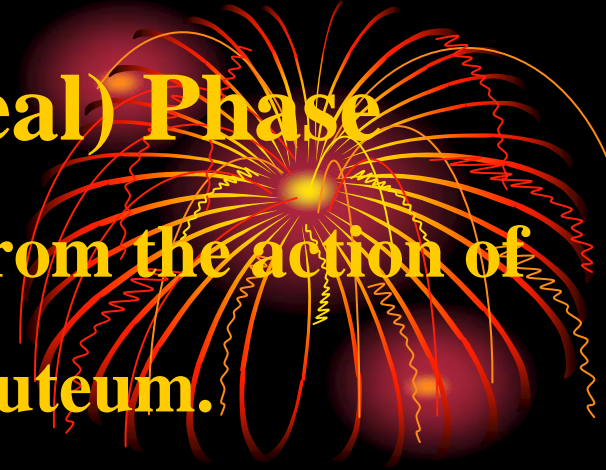




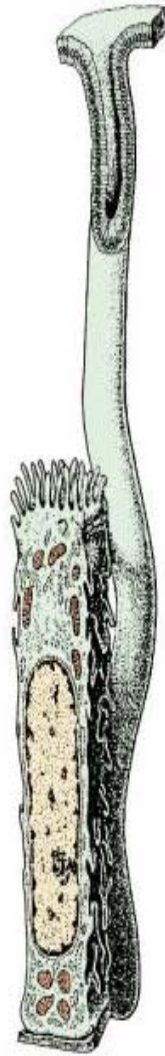
2. The Secretory (Luteal) Phase

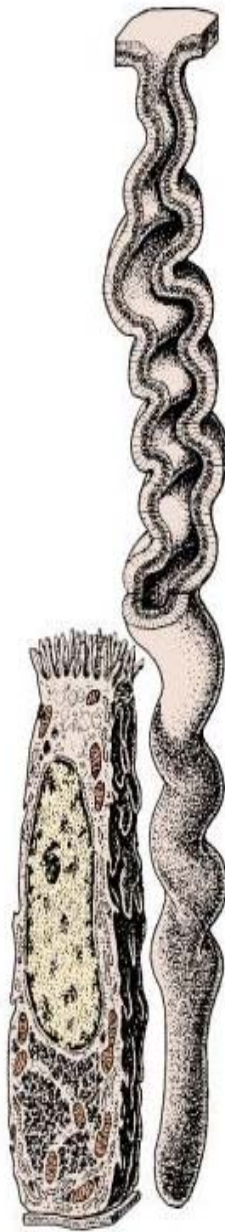- **It starts after ovulation and results from the action of progesterone secreted by the corpus luteum.**
- **The epithelial cells of glands begin to accumulate glycogen. Later, the amount of glycogen diminishes, and glycoprotein secretory products dilate the lumens of the glands. the glands become highly coiled .**
- **In this phase, the endometrium reaches its maximum thickness (5 mm) as a result of the accumulation of secretions and of edema in the stroma.**



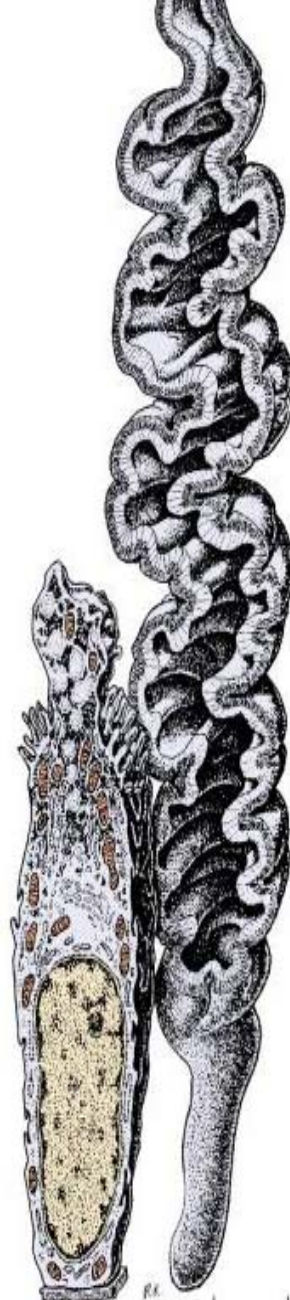0.5 mm



End of proliferative phase





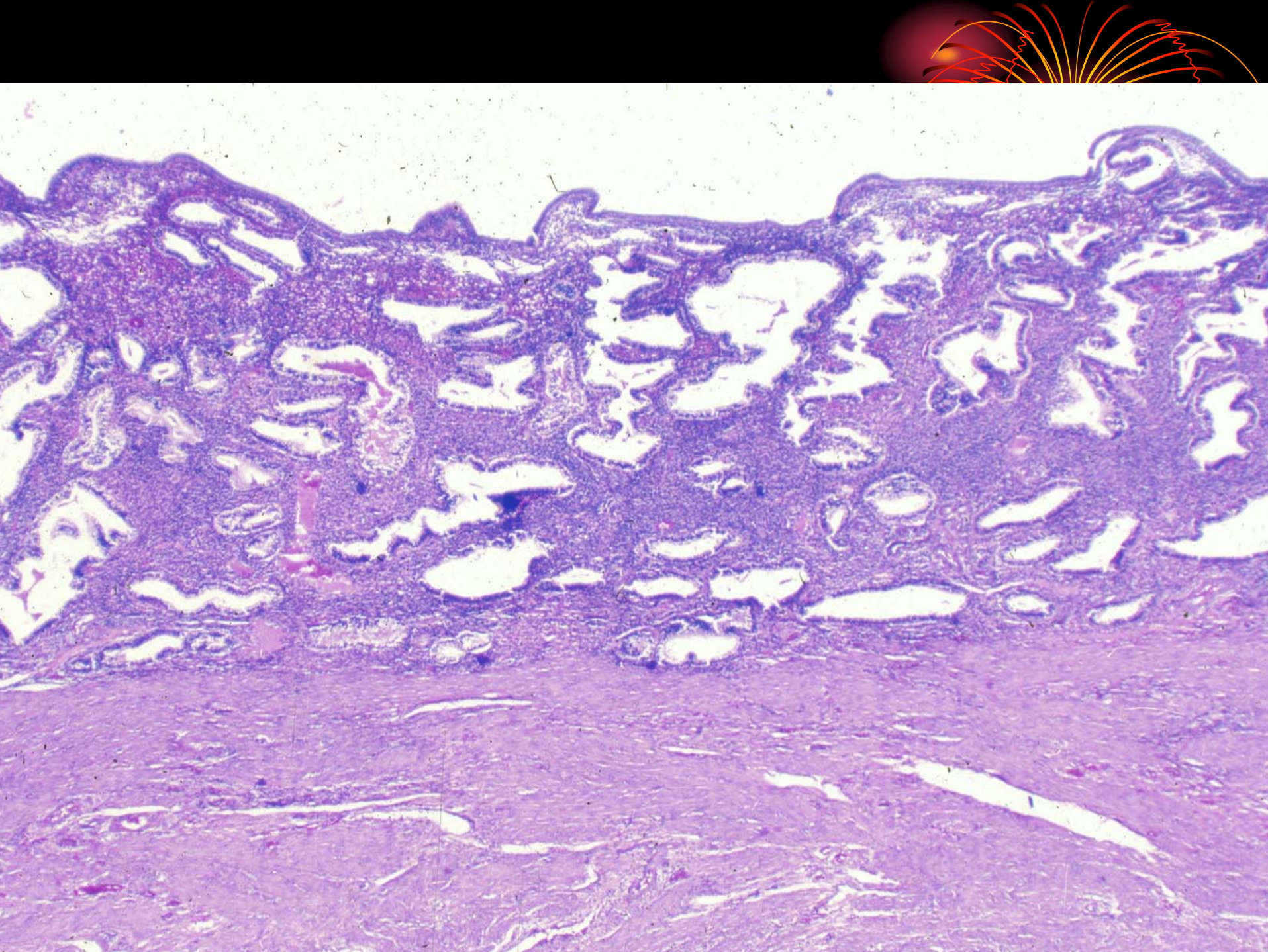
Initial secretory phase



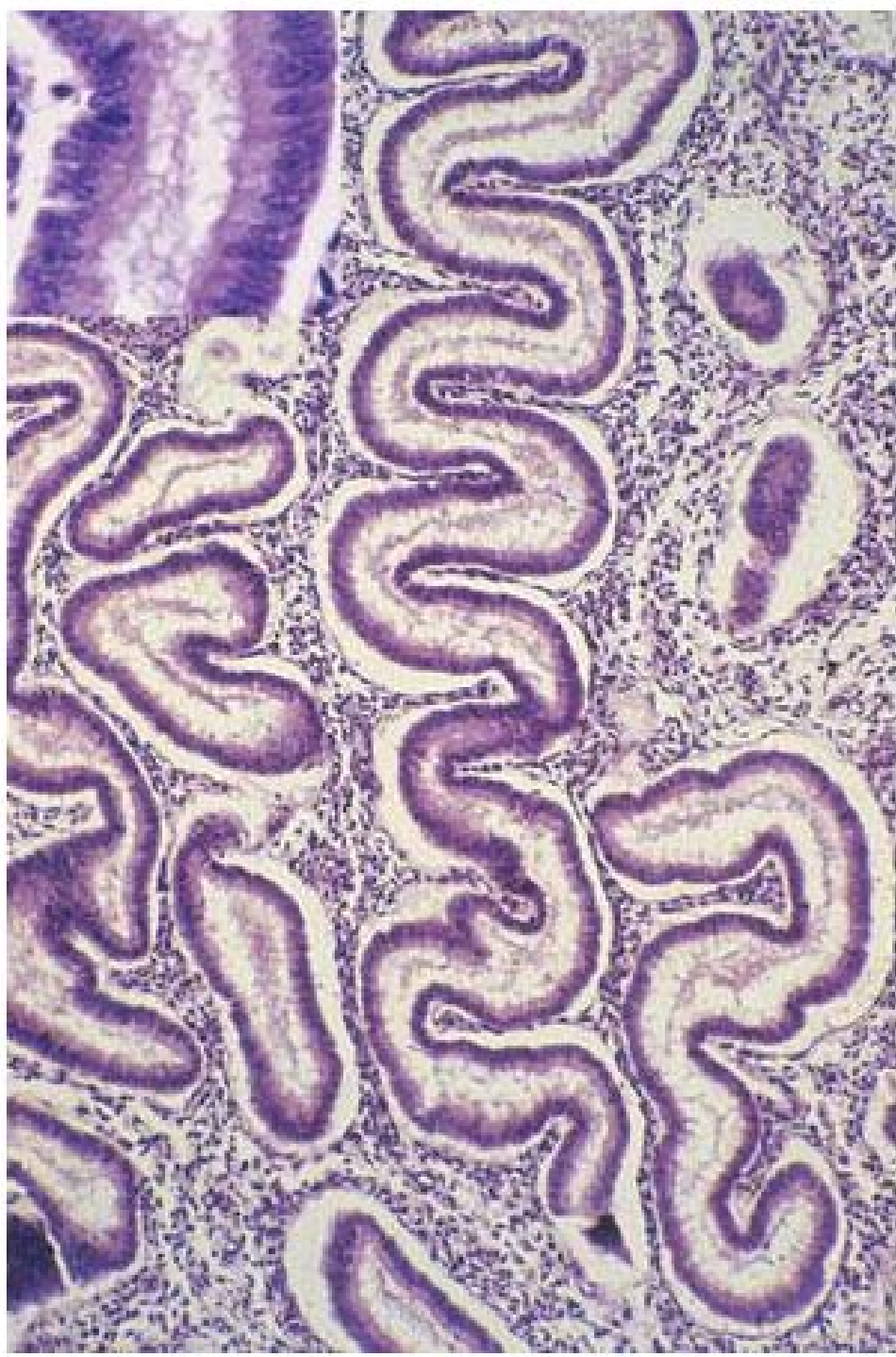


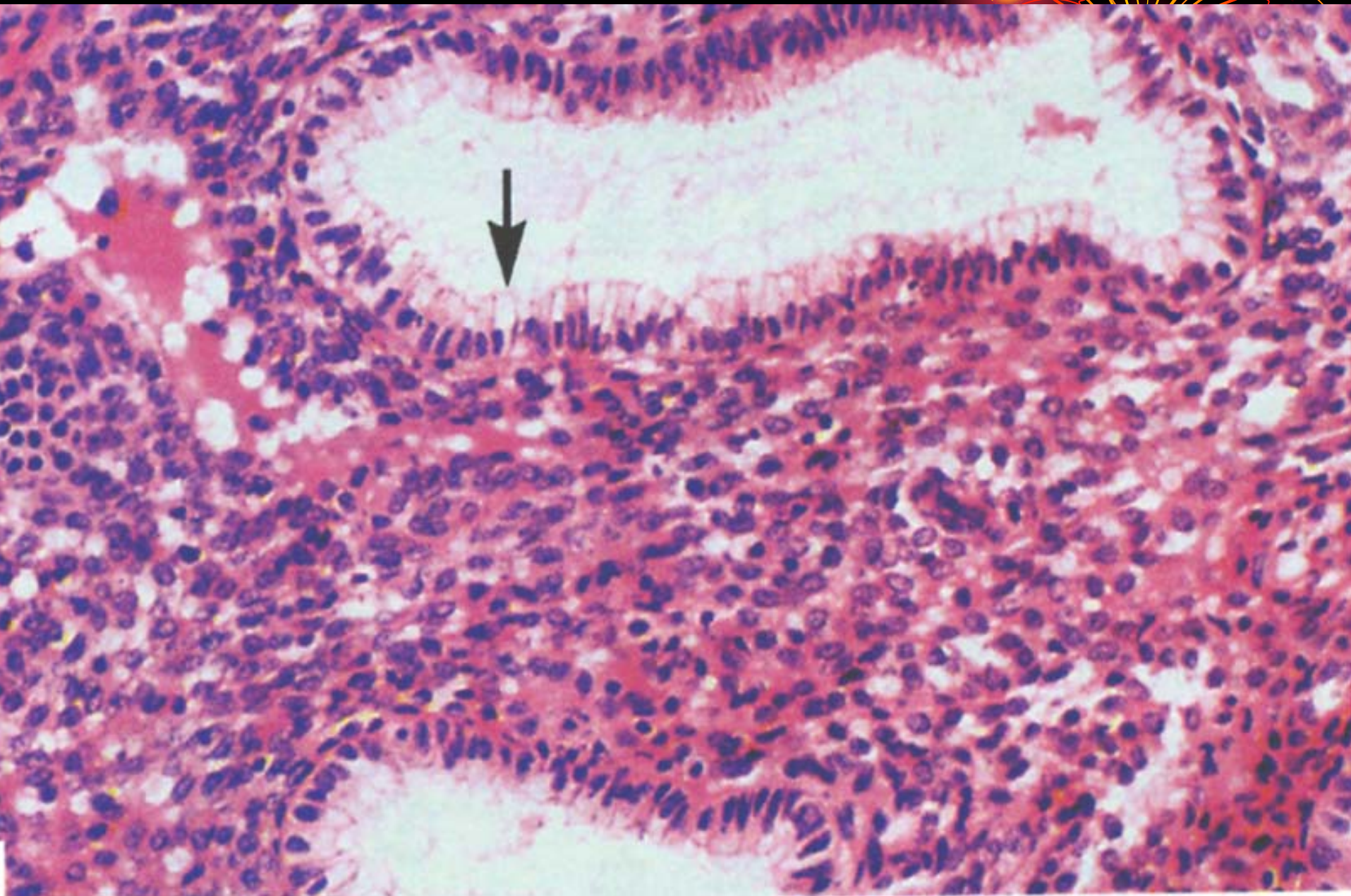
Late secretory phase

5 μ m



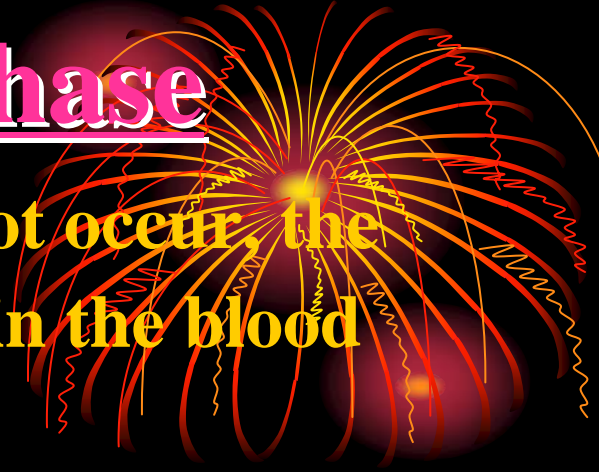


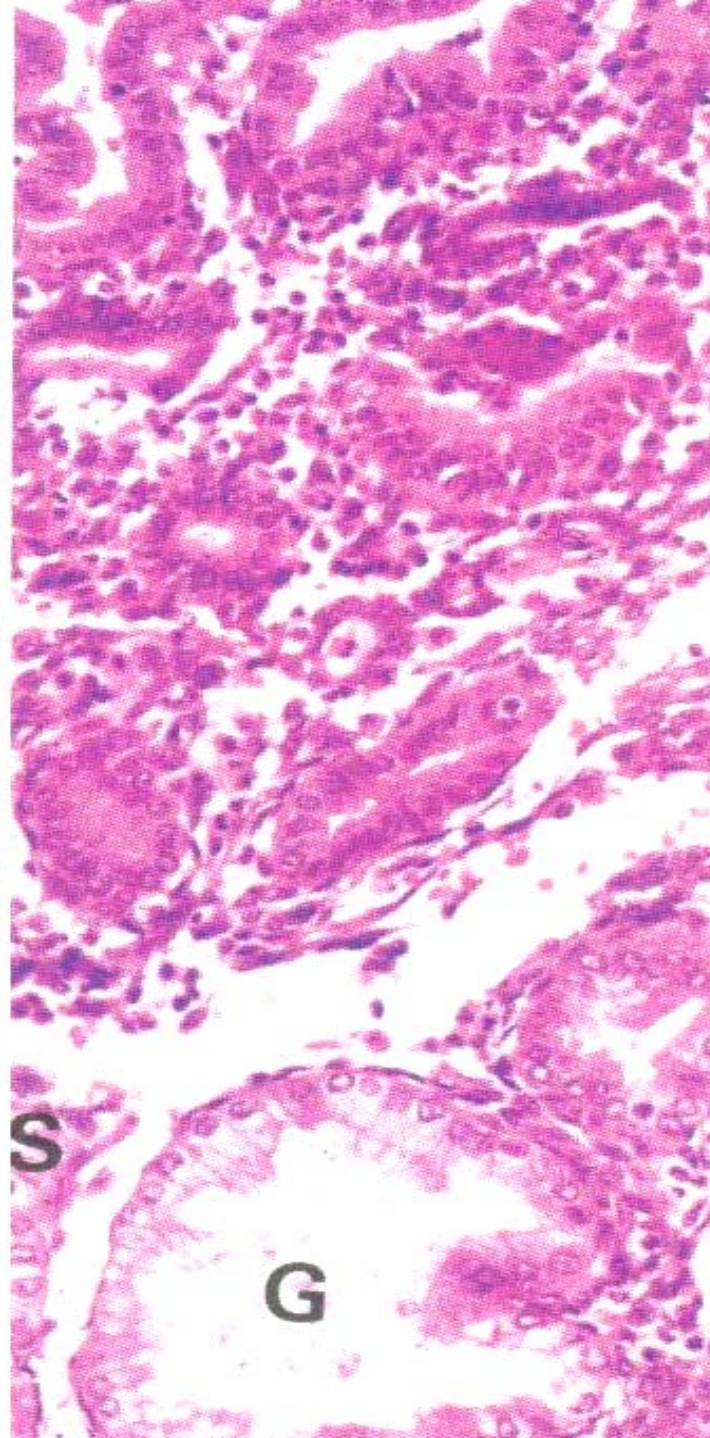
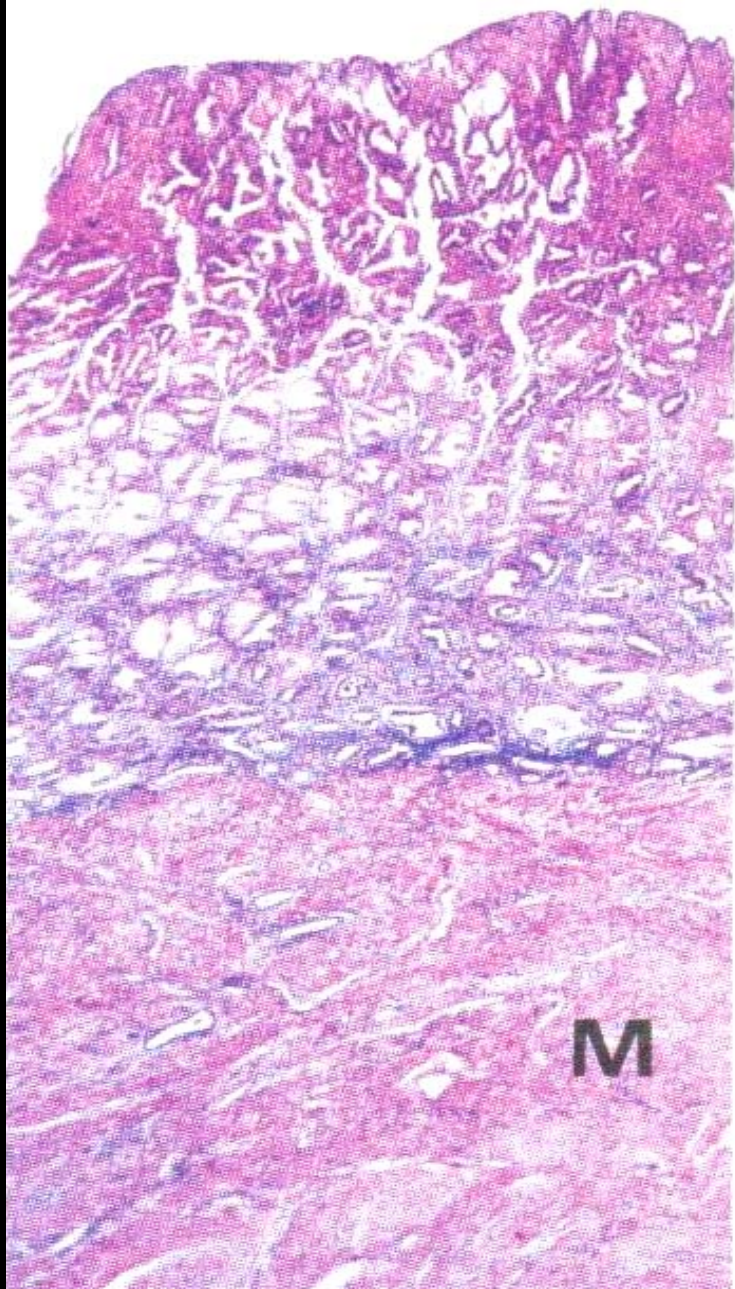




3. The menstrual phase

- **When fertilization of the oocyte do not occur, the levels of progesterone and estrogens in the blood decrease rapidly.**
- **This causes contraction of the spiral arteries, closing off the blood flow and producing ischemia, which leads to death of their walls and of part of the functionalis layer of the endometrium. Blood vessels rupture and bleeding begins.**
- **At the end of the menstrual phase, the endometrium is usually reduced to a thin layer.**
- **The endometrium is thus ready to begin a new cycle as its cells begin dividing to reconstitute the mucosa.**



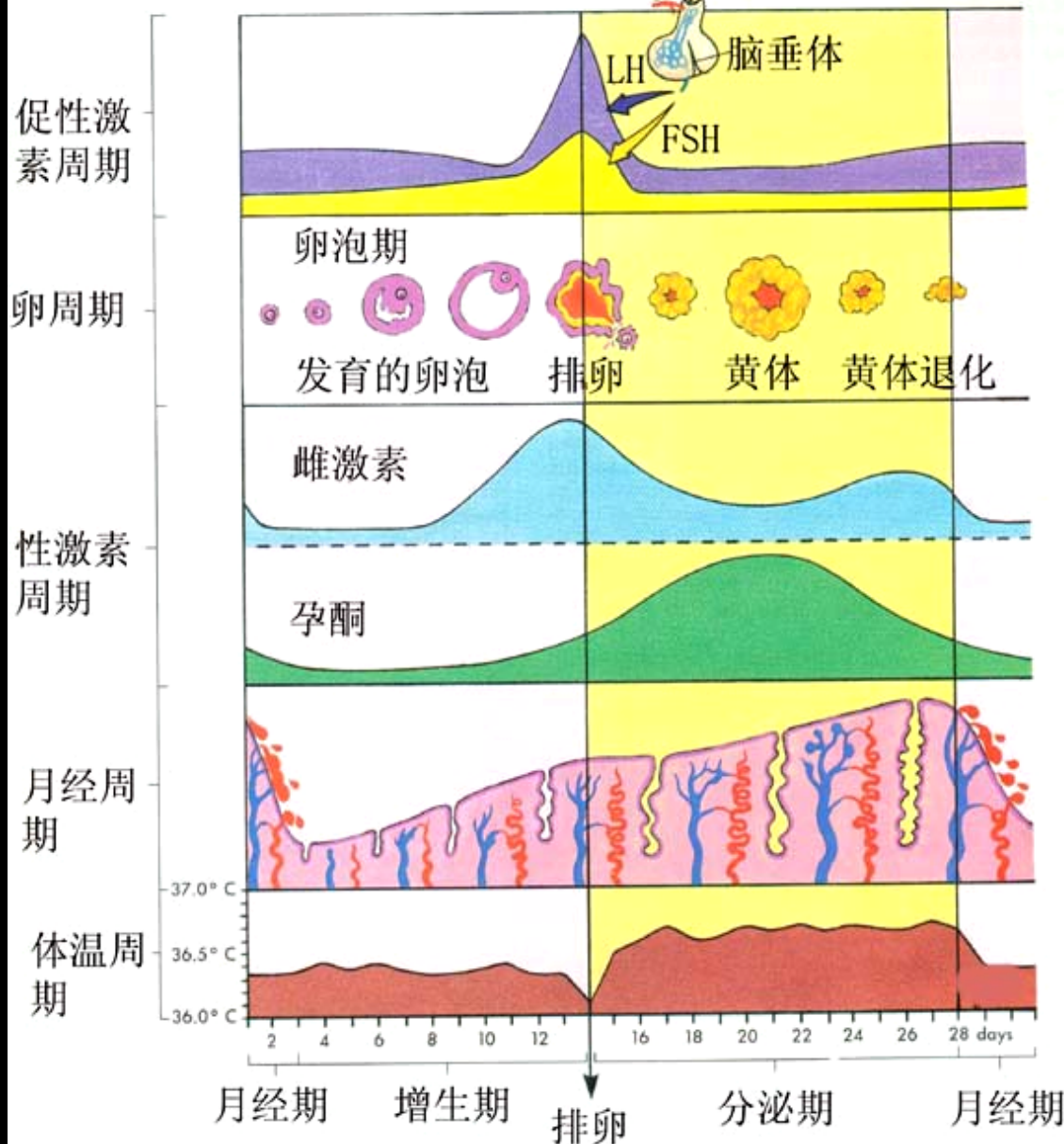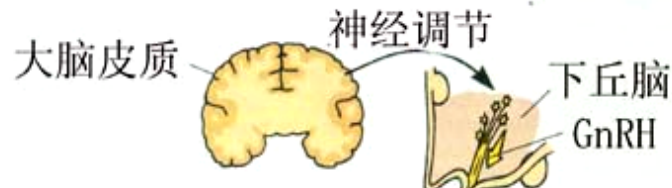




Relationship between ovary and menstrual cycles

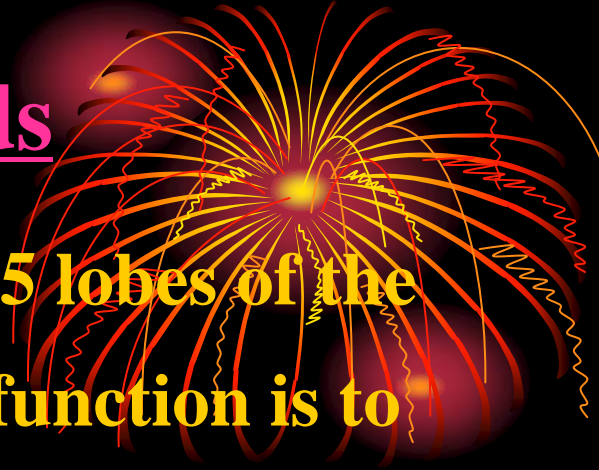

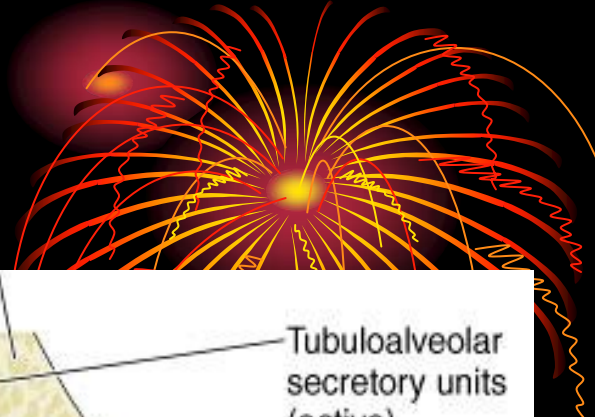
	Stage of Cycle				
	Proliferative	Secretory or Luteal			Menstrua
Main actions of pituitary hormones	Follicle-stimulating hormone stimulates rapid growth of ovarian follicles.	Peak of luteinizing hormone at the beginning of secretory stage, secreted by stimulation of estrogen, induces ovulation and development of the corpus luteum.			
Main events in the ovary	Growth of ovarian follicles; dominant follicle reaches preovulatory stage.	Ovulation.	Development of the corpus luteum.	Degeneration of the corpus luteum.	
Dominant ovarian hormone	Estrogens, produced by the growing follicles, act on vagina, tubes, and uterus.	Progesterone, produced by the corpus luteum, acts mainly on the uterus.		Progesterone production ceases.	
Main events in the endometrium	Growth of the mucosa after menstruation.	Further growth of the mucosa, coiling of glands, secretion.	Shedding of part of the mucosa about 14 days after ovulation.		



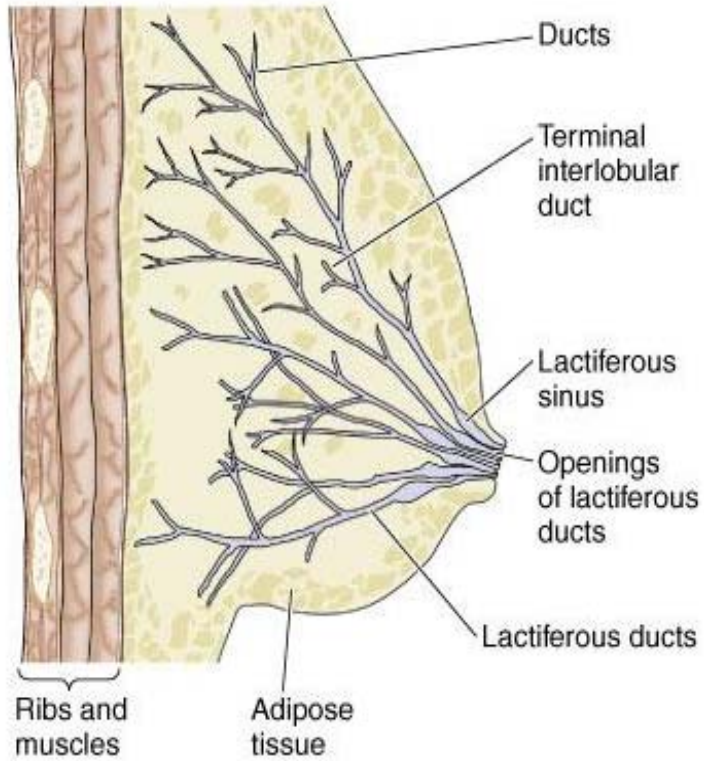
III. Mammary glands

- **Each mammary gland consists of 15–25 lobes of the compound tubuloalveolar type whose function is to secrete milk to nourish newborns.**
- **Each lobe, separated from the others by dense connective tissue and much adipose tissue, is really a gland in itself with its own excretory lactiferous duct . emerge independently in the nipple.**
- **The histologic structure of the mammary glands varies according to sex, age, and physiologic condition**

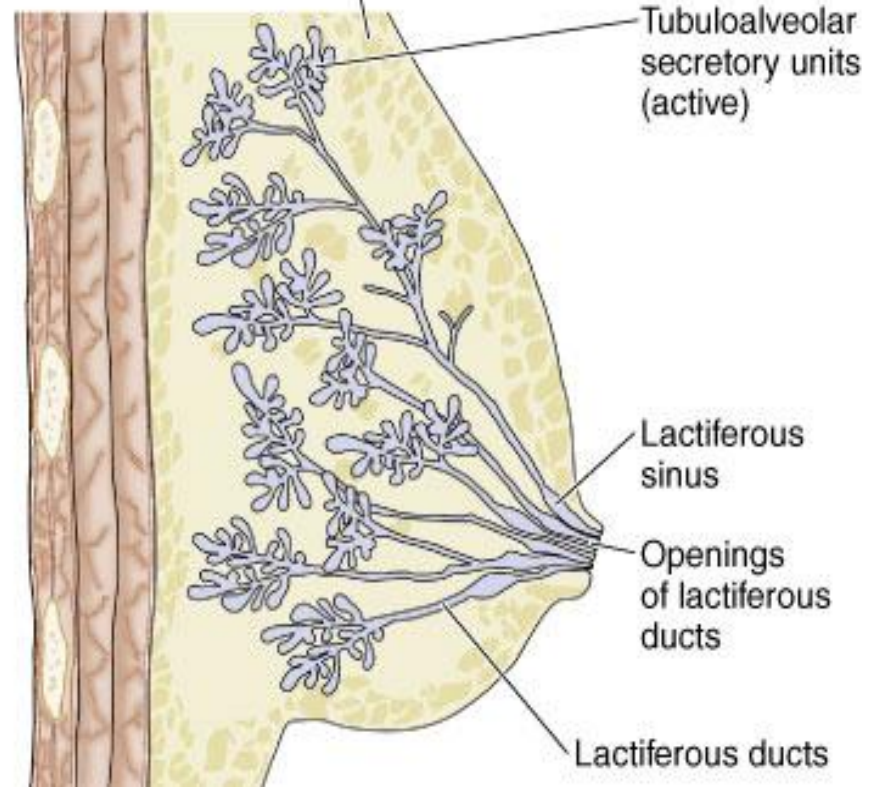




Inactive

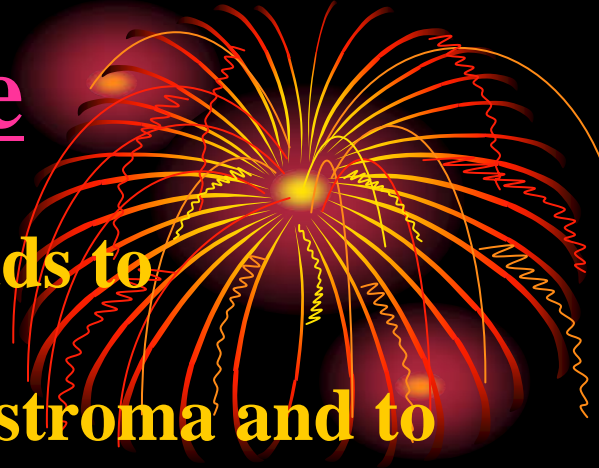

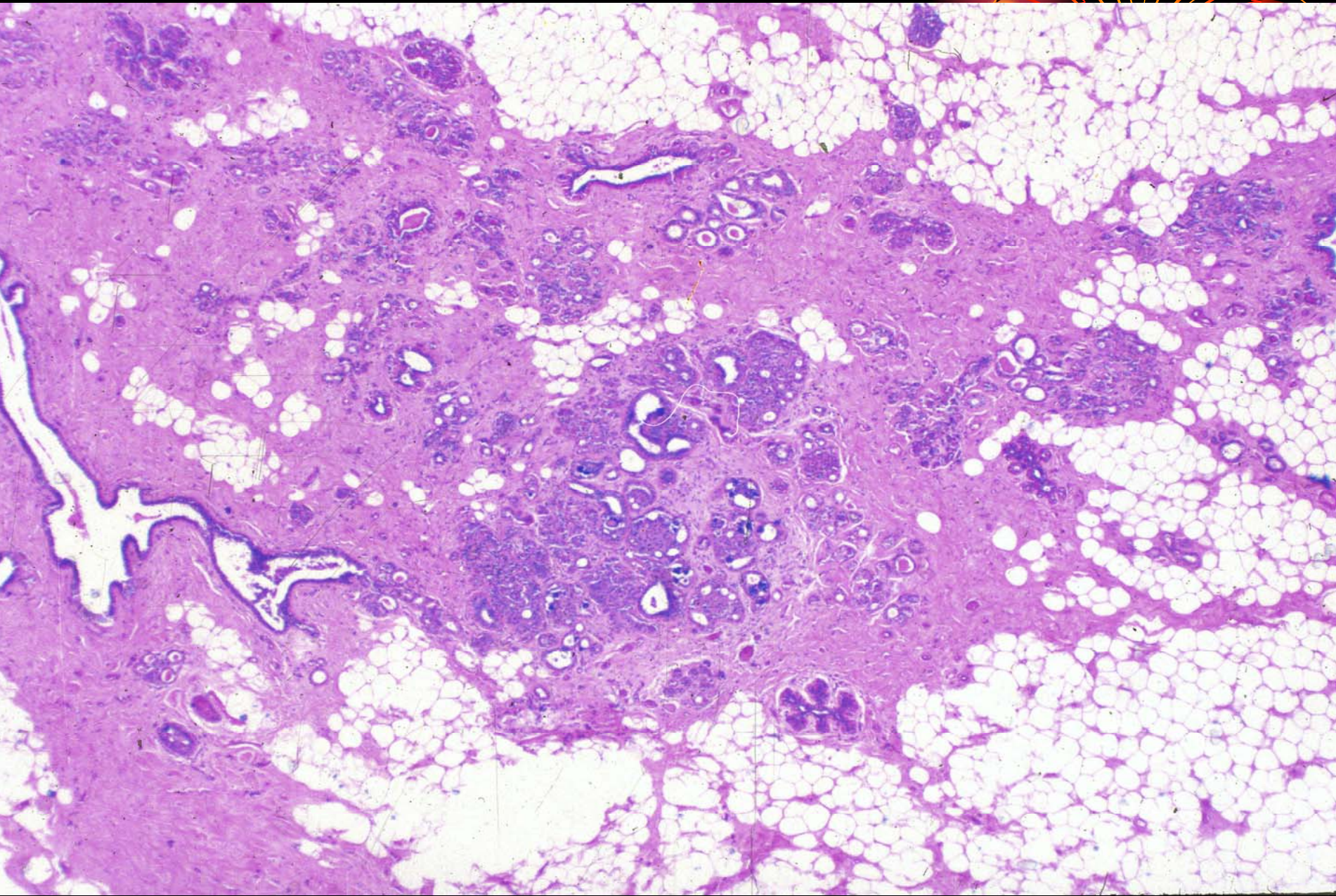
Active



1. Inactive state

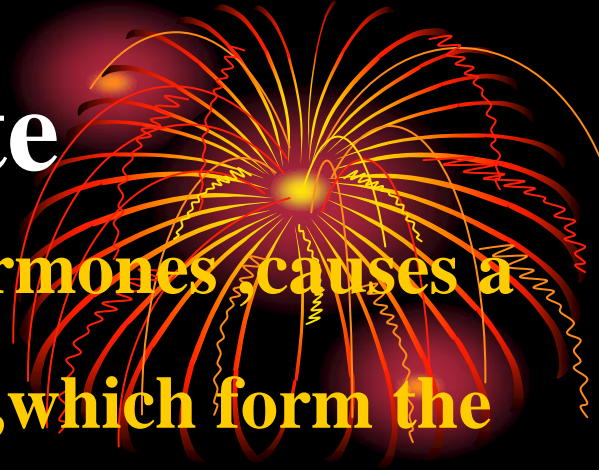- ◆ **Stimulation by ovarian hormones leads to accumulation of adipose tissue in the stroma and to formation of terminal ductules**
- ◆ **During the secretory phase of the menstrual cycle, progesterone and oestrogens also cause a proliferation of the terminal ductules**
- ◆ **After the climacteric, the mammary glands undergo progressive atrophy**





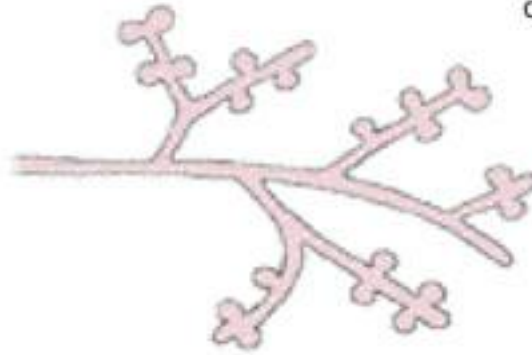
2. Pregnant state

- **During pregnancy, stimulation by hormones causes a proliferation of the terminal ductules, which form the secretory alveoli.**
- **In the fifth month of gestation, alveoli develop and lumina appear . The adipose tissue decreases considerably.**
- **In the ninth month there is also a secretion of a fluid termed colostrum**



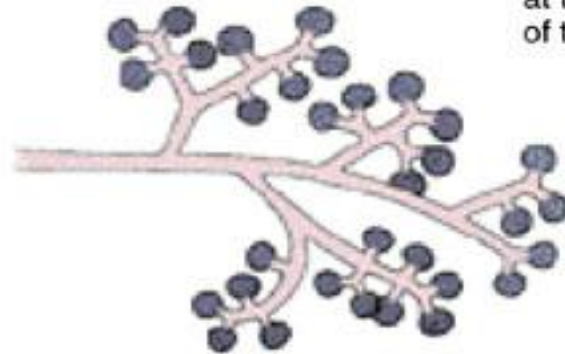
A Nonpregnant

Inactive
duct system





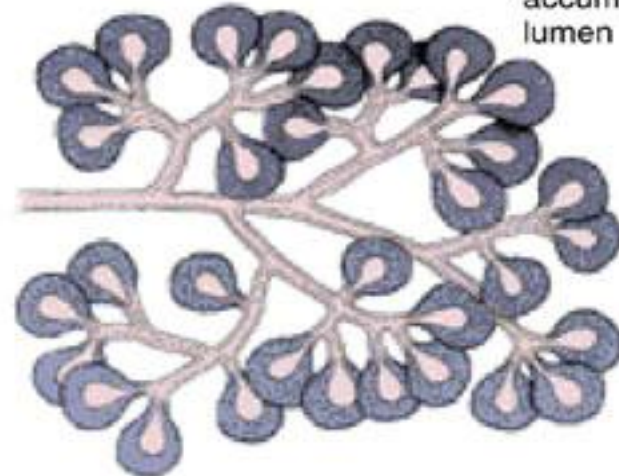
B During pregnancy

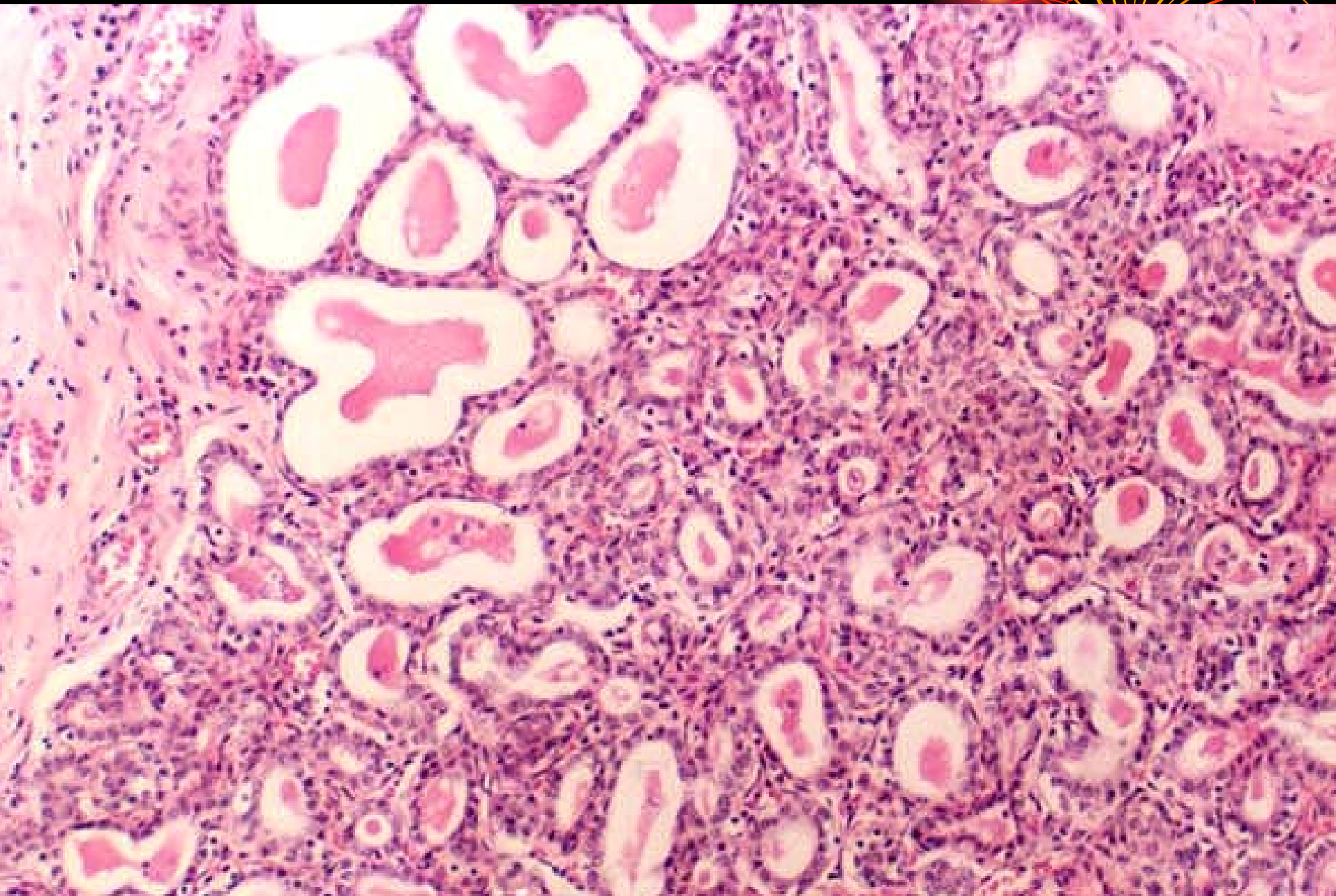
Alveoli proliferate
at the ends
of the ducts



C Lactating

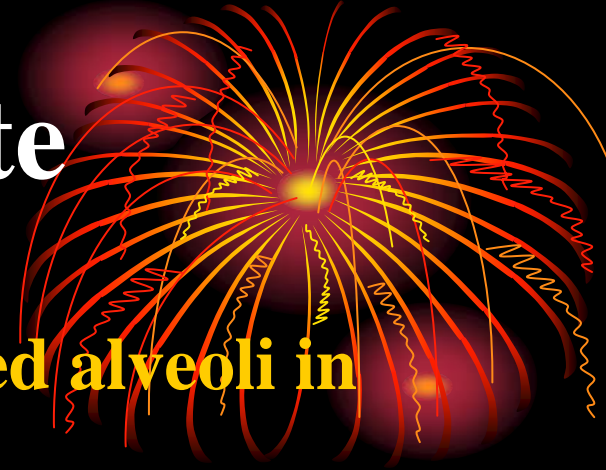
Milk secretion and
accumulation in alveolar
lumen


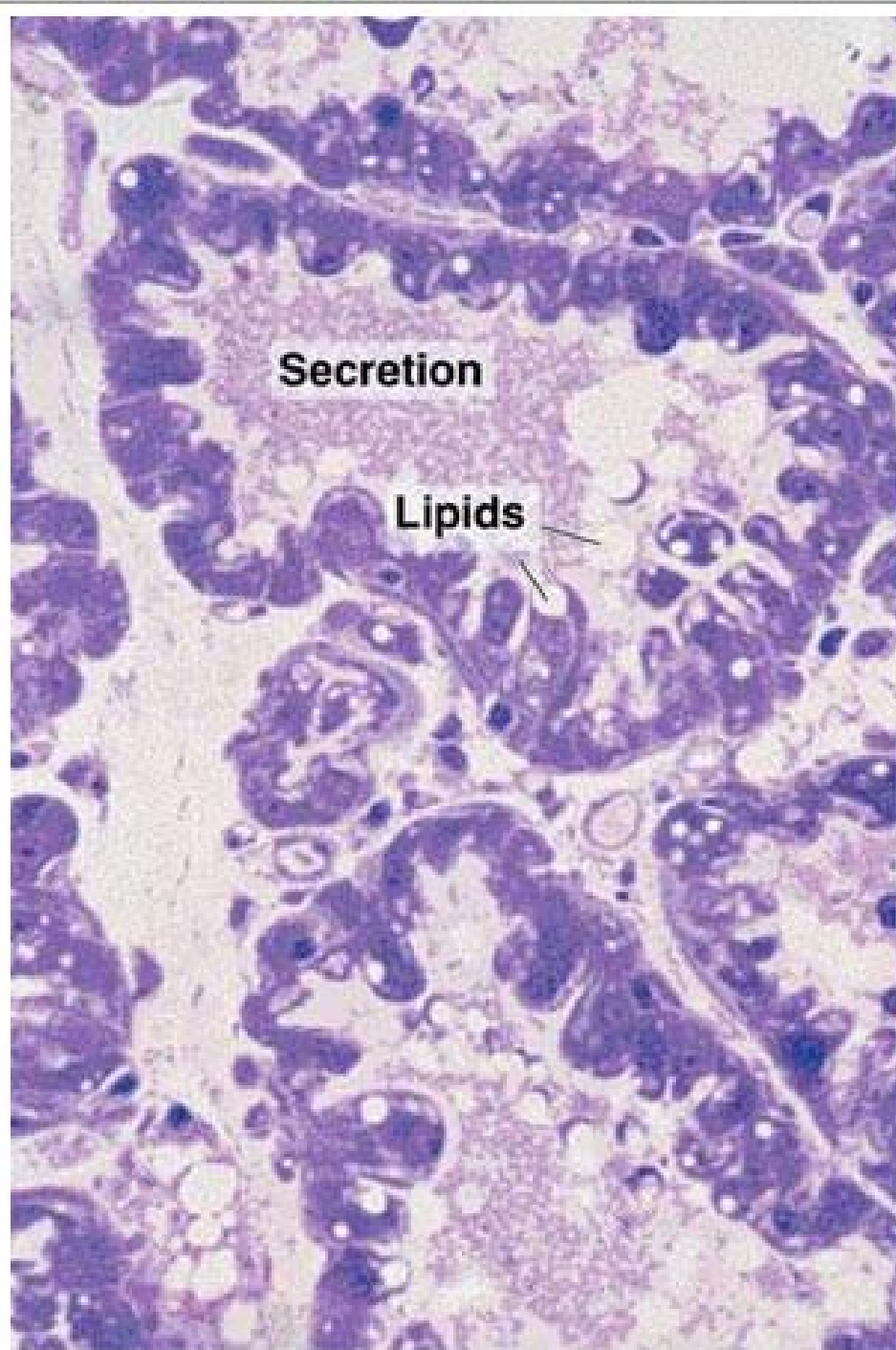


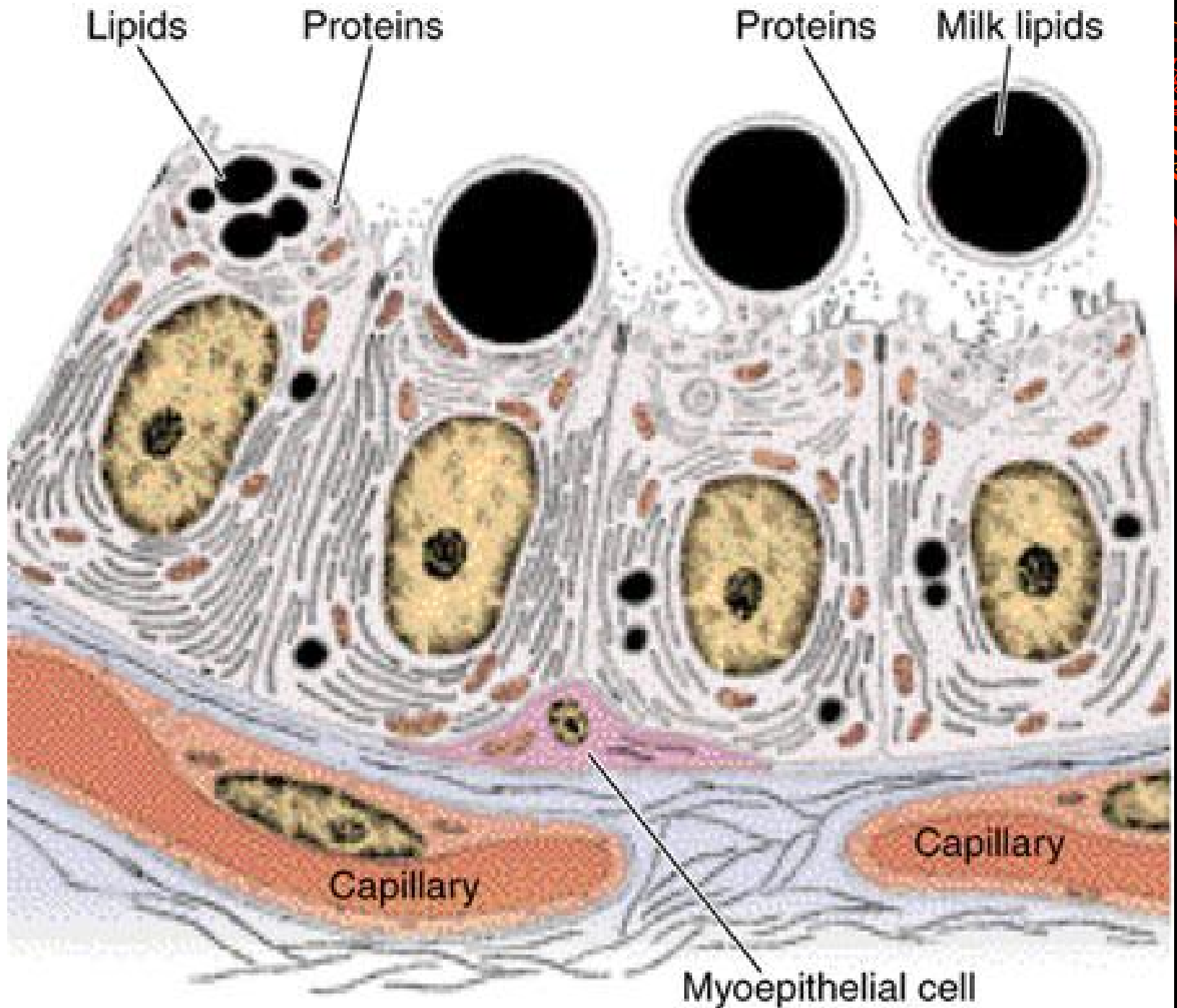


3. Lactating state

- **The glands contains well-developed alveoli in different secretory phases**
- **Some alveoli show large cells filled with secretion, while others show cuboidal or squamous cells and large lumen containing milk.**







Lipids

Proteins

Proteins

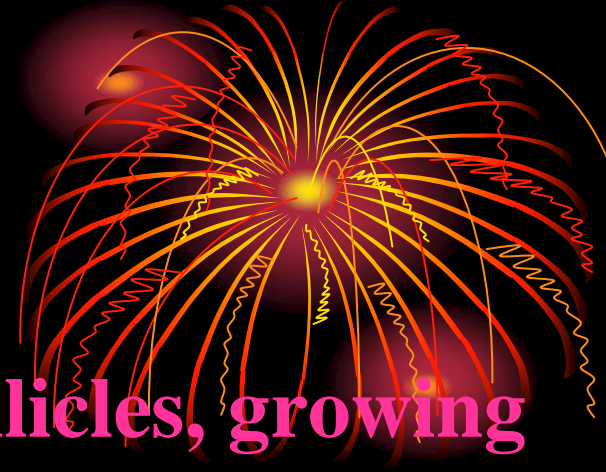Milk lipids

Capillary

Capillary

Myoepithelial cell

summary



- **The structure of primordial follicles, growing follicles and mature follicles**
- **Ovulation**
- **The structure and function of Corpus Luteum**
- **The menstrual cycle**

